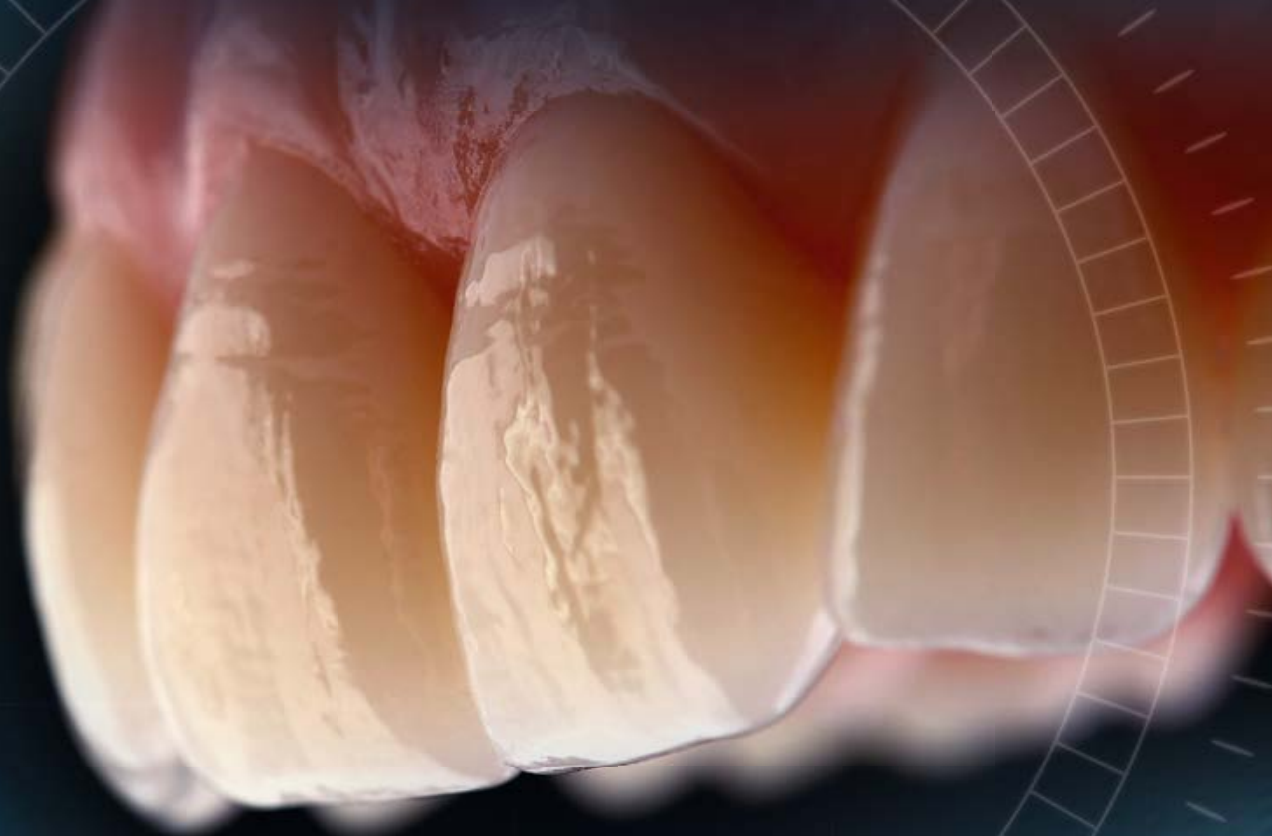

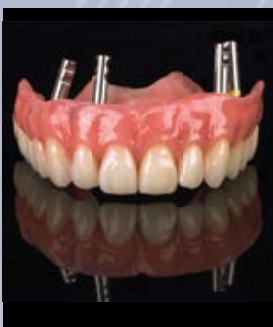DENTAL

VISIONIST



Success principles for the efficient production of natural-looking prosthetics

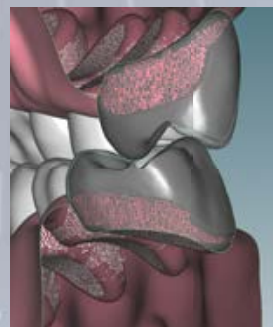
How to achieve predictable, esthetic and functional results.



New generation of premium, anterior denture teeth with golden proportions

Carolin Wehning, Dental Technician, reports on her experience with the manufacturing of an implant-supported maxillary prosthesis.

> [Page 16](#)



CAD/CAM prostheses at the touch of a button

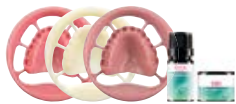In this case example, find out how you can manufacture prostheses today using digital processes.

> [Page 29](#)

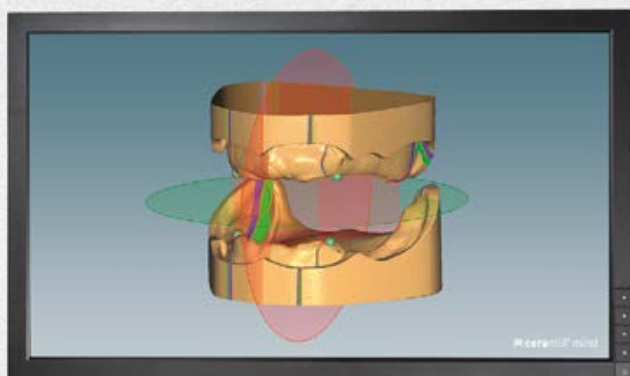
PRECISE, INDIVIDUAL,
AESTHETIC.

 **ceramil® fds**

NEW
VITA



VITA VIONIC SOLUTIONS -
the matched materials system for
the digital fabrication of dentures
with Ceramil FDS.



*"I'm convinced by Ceramil FDS,
because despite all the innovation,
it always puts the patient first."*

Karl-Heinz Körholz | www.trigodent.de

Editorial

Success principles for predictable, perfectly shaped and functional results



Predictable, perfectly shaped and functional results require, in addition to dental experience, denture teeth that comply with the standards set by nature. For ideal restoration results, an anterior tooth requires perfectly aligned tooth axes, length-width ratios and a natural angle and curvature characteristics. VITAPAN EXCELL was created with these golden proportions in mind.

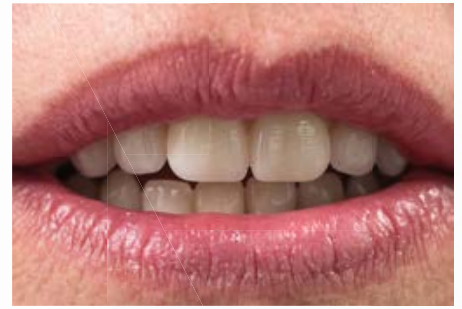In this DENTAL VISIONIST edition, dental technicians demonstrate how to achieve reproducible esthetic results using numerous case examples that they have produced with the new generation of anterior denture teeth, VITAPAN EXCELL.

This edition also addresses the differences between tooth materials and how wear resistant these dental products have shown to be in testing. Finally, we introduce the new topic of "digital prosthetics."

This special edition of the DENTAL VISIONIST is dedicated exclusively to the topic of prosthetics, from setup through lifelike reproduction of the gingiva.

DENTAL VISIONIST wishes you an enjoyable read!

Felicitas Ledig
Chief Editor

**New anterior tooth for a new generation of patients**

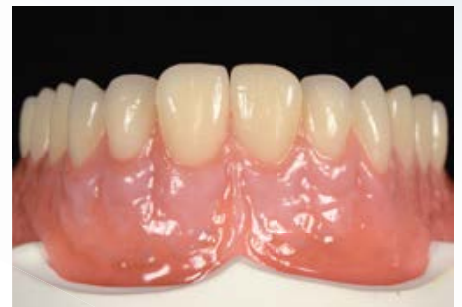Natural dental restoration that highlights vitality.

> Page 20

**Various tooth materials tested**

High durability with MRP composite.

> Page 6

**The gingiva is naturally reproduced**

Essential individualization steps explained, step by step.

> Page 24

PUBLICATION DETAILS**Publisher**

VITA Zahnfabrik H. Rauter GmbH & Co. KG
Spitalgasse 3 | 79713 Bad Säckingen

Editorial Production/Design/Layout

qu-int. marken | medien | kommunikation
Waldkircher Straße 12 | 79106 Freiburg

Chief Editor

Felicitas Ledig
qu-int. brands | media | communication
Waldkircher Straße 12 | 79106 Freiburg

Publication: two issues per year

Copyright and publishing rights:

Articles do not necessarily reflect the views of the editorial team. The product information published is accurate to the best of our knowledge. This does not, however, constitute a warranty. All rights reserved, in particular the right to reproduction (in any form), as well as the right to translation into foreign languages.

Trademark rights:

VITA and VITA Products are registered trademarks of VITA Zahnfabrik H. Rauter GmbH & Co. KG, Bad Säckingen, Germany. All other company names and/or products mentioned in this journal are or may be registered trademarks of the corresponding companies and/or trademark holders.

INFORMATION

The testimonials by dentists and dental technicians published in this magazine are based on practical experience with the specified VITA materials gained during the course of processing, and/or on manufacturer information based on the data provided in the technical and scientific documentation (VITA Zahnfabrik, Bad Säckingen, Germany; download from www.vita-zahnfabrik.com). The statements of the named dentists and dental technicians reflect the status of the report authorization of 07/2017. The testimonials by developers or technical marketing department published in this magazine are based on individual and/or internal studies conducted by VITA R&D (VITA Zahnfabrik, Bad Säckingen, Germany) and/or on the results of pilot testing.

Materials and procedures in tooth production: MRP composite versus PMMA



*Dr. Stefan Aechtner
Bad Säckingen, Germany*

Today, the denture teeth available on the market are mostly manufactured from polymethyl methacrylate (PMMA). In contrast to the classic "PMMA denture teeth," VITA manufactures the majority of its dental products from MRP composite (Microfiller Reinforced Polymer Matrix). This is a highly crosslinked polymer matrix with homogeneously distributed, inorganic polymerized microfillers. In the following article, Dr. Stefan Aechtner (Project Manager for Material Development at VITA R&D, Bad Säckingen, Germany) explains the central differences in materials and procedures in industrial tooth manufacturing.

Characteristics of dental materials

During manufacture of the VITA MRP composite, the silicon dioxide fillers (SiO_2 /pyrogenic silica) are surface modified or silanized at VITA in a special process to ensure excellent bonding to the PMMA matrix. The SiO_2 filler acts as an additional crosslinking agent during polymerization. The strengthening of the polymer matrix with microfillers ensures an excellent wear resistance for MRP composite products. PMMA materials (polymethyl methacrylate), on the other hand, are a synthetic acrylic without inorganic fillers. PMMA denture teeth exhibit comparably lower durability in tests than dental products made of composite.

Procedures for fabricating teeth

In general, today's modern denture teeth are built up layer-by-layer from different types of material. However, there are fundamental differences in tooth manufacture, depending on the material base. With MRP composite, the different materials are layered, one after the other, into the tooth molds until the mold is completely filled. After this, the materials are compacted and cured under pressure and heat. The polymerization of the entire denture tooth is done in a single step. The materials penetrate each other completely at their boundary layers and a gap-free and pore-free bond is achieved. In the case of PMMA prefabricated teeth, the materials are successively layered or pressed into the tooth molds. Here, each individual layer is fixed in position by heating under pressure to ensure that the mold can be opened for introducing the next layer. Finally, the final polymerization follows, which fully polymerizes the material.

100% German Dental Engineering

VITA is committed to the motto of "100% German Dental Engineering," and has been combining German engineering skill with practical dental knowledge and technology since 1924. VITA denture teeth are made from MRP composite and manufactured according to the highest production and quality standards, exclusively in southern Germany, at the company's headquarters. Here, specially trained, skilled personnel produce the denture teeth using both automated processes and customized manual production.

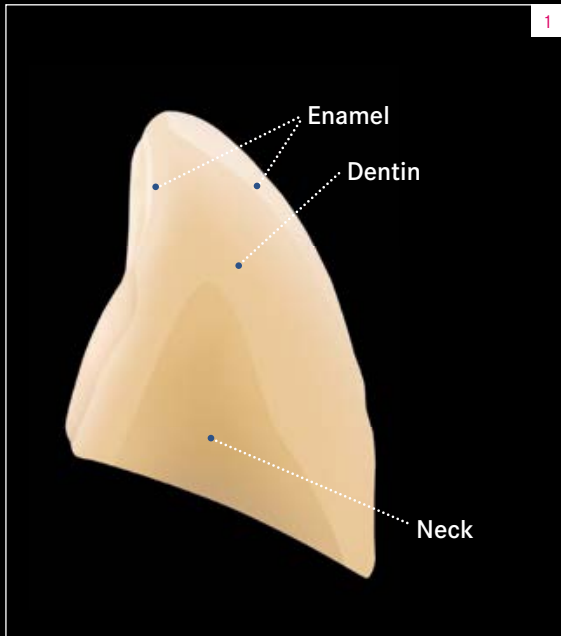


Fig. 1 Schematic of layered construction of a new generation VITA denture tooth (VITAPAN EXCELL).

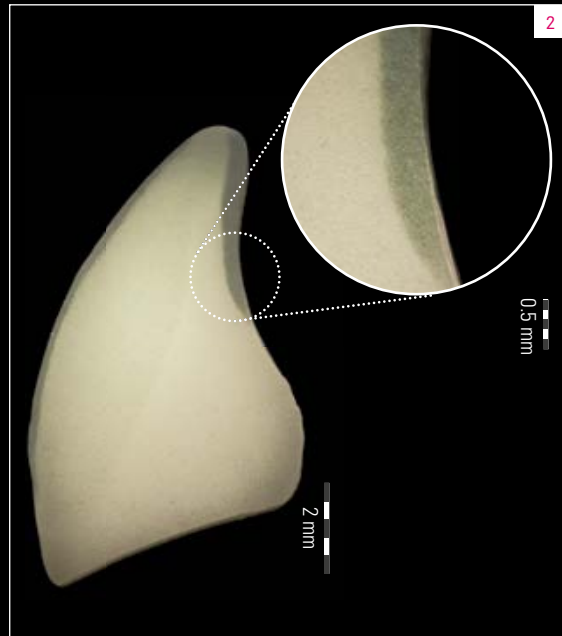


Fig. 2 The cross-sectional image of an MRP composite dental product (here VITAPAN EXCELL) generated by light microscopy, also shows a gap-free and pore-free bond in the boundary layers.

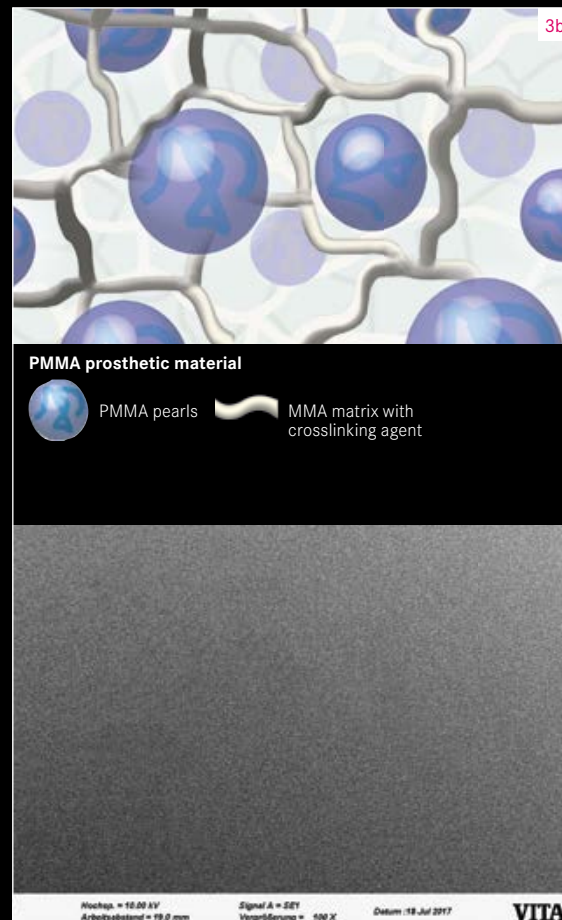
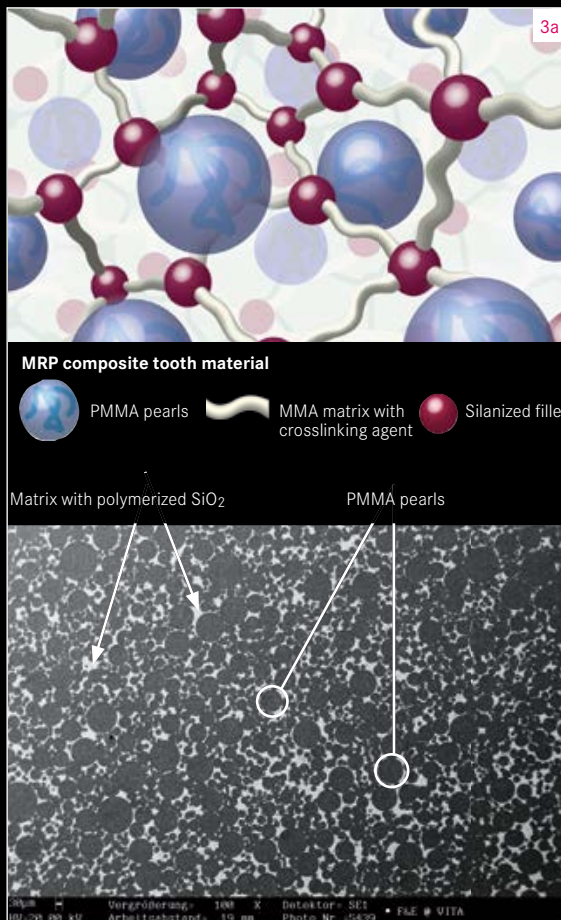


Fig. 3a/b Comparison of MRP composite (left) and PMMA (right) using schematic representations of the material structure and scanning electron microscope (SEM) images.

Denture materials tested: High durability for MRP composite!

The abrasion resistance of the denture teeth has a significant influence on the functional and esthetic long-term success of the prosthetic restoration. Increased material removal is always accompanied by a lowering of the bite, which adversely affects all anatomical structures of the stomatognathic system and can lead to esthetic deficits. In the following interview, Prof. Dr. Martin Rosentritt (Regensburg University Hospital, Germany) reports on in-vitro testing of the wear resistance of ready-to-use teeth and his experience with VITA denture teeth made of MRP composite (Microfiller Reinforced Polymer Matrix).

Wear study

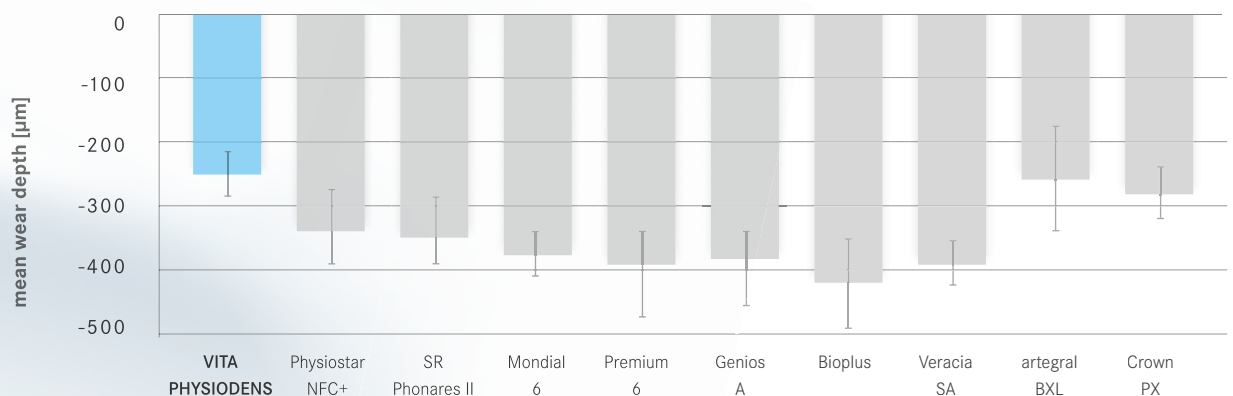


Fig. 1 Results graph of the determined average wear depth per dental product (eight test specimens per product) after wear testing in the chewing simulator.

Source: University of Regensburg, Prof. Dr. M. Rosentritt, Test Report No. 280_2, Report 11/15; published in Tech.-Wiss. Dokumentation VITA Prothesenzähne [Technical-Scientific Documentation of VITA Prosthetic Teeth], download via www.vita-zahnfabrik.com/prosthetics



Prof. Dr. Martin Rosentritt
Regensburg, Germany

DV: Which denture teeth made of which materials have you investigated?

Dr. M. Rosentritt: We have investigated a total of ten prefabricated products of different manufacturers in relation to their abrasion stability. The denture teeth showed differences due to both the material and the manufacturing method used. Some of the examined prefabricated teeth were made of pure polymer, while other brands showed that only the outer layers contained fillers. Finally there were also denture teeth like the VITA PHYSIODENS, which were made entirely of composite.

"VITA tooth products made of MRP composite allow the expectation of good clinical durability."

DV: What test procedure did you use in your in-vitro study?

Dr. M. Rosentritt: We conducted a pin-on-block (POB) wear test in the chewing simulator on embedded denture teeth. A steatite ball with a force of 50 N and a pulse of 1.2 Hz was passed over the respective prefabricated teeth in 120,000 cycles. To simulate a temperature load alternation between 5° and 55° C, temperature-controlled distilled water was used to rinse the teeth.

DV: Based on the results, what can we expect regarding the long-term durability of the denture teeth?

Dr. M. Rosentritt: The VITA PHYSIODENS denture teeth of MRP composite showed significantly less wear in the test in comparison to the other tested denture teeth. According to these results, we can expect that VITA prefabricated teeth made of MRP composite provide clinically longer lasting durability.

DV: What explains the good abrasion stability of the VITA prefabricated product in the test?

Dr. M. Rosentritt: Like the majority of the VITA denture teeth, the VITA PHYSIODENS is manufactured from MRP composite material. This is a high molecular weight, highly cross-linked acrylate polymer with silanized and homogeneously incorporated silicon dioxide microfill bodies, which are polymerized into the polymer matrix. This microfiller also strengthens the polymer matrix, which contributes to its good durability. In addition, VITA uses a special process to compact and cure all tooth layers at the same time so that boundary layers penetrate completely.

DV: What should technicians pay attention to during manufacture to ensure durable prosthetics?

Dr. M. Rosentritt: The prosthetic setup should harmonize with the stomatognathic system. In parafunctions, the chewing load is always increased and abrasive processes are increasingly reduced. Chewing surfaces should be polished again after grinding to avoid abrasive surfaces.

Report 07/17



Fig. 2 The pin-on-block (POB) wear test was conducted on eight different samples per product with a steatite ball.

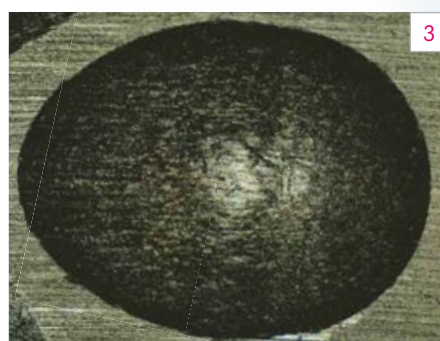


Fig. 3 Typical wear trace after chewing simulation at high magnification by means of a scanning electron microscope (SEM).

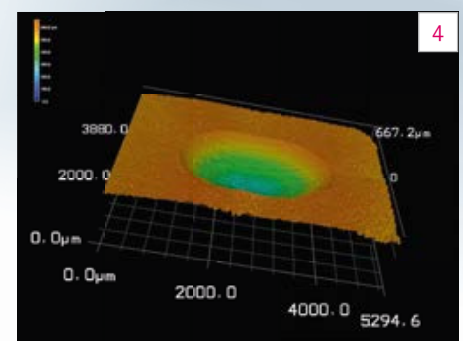


Fig. 4 After analysis of the samples using 3D laser microscopy, significantly lower maximum wear was determined for VITA PHYSIODENS made of MRP composite in comparison.

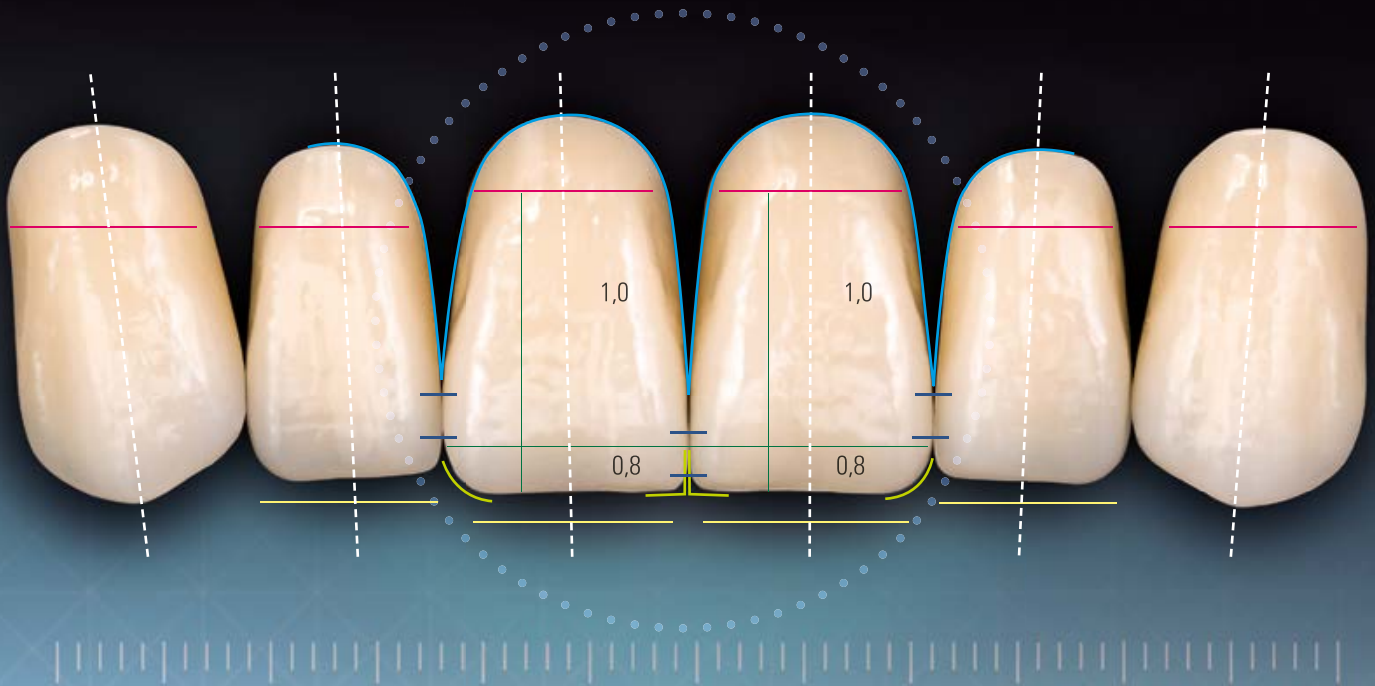


Image: VITAPAN EXCELL anterior tooth; geometry: R49

■ tooth axes
 ■ contact surfaces
 ■ angle features
 ■ cervical dimensions
 ■ gingival transition
 ■ length/width ratio

"The golden proportions:"

Essential principles of success for esthetic prosthetics



Master Dental Technician
 Claus Pukropp
 Bad Säckingen, Germany

Since ancient times, the search for the "esthetic formula" has been pursued. Research shows that we perceive faces as especially esthetic if they are characterized by a high degree of "order," "proportionality" and "symmetry." However, the total symmetry is quickly perceived as unnatural [Fig. 1, 2]. Essential esthetic principles can also be transferred to total and partial restorations. For a restoration to be harmoniously integrated, parameters such as the basic anatomical shape of the anterior teeth, their length/width ratio, the tooth axes and the gingival transition are extremely important. In his report, Claus Pukropp, Master Dental Technician (Head of Technical Marketing, VITA Zahnfabrik, Bad Säckingen) describes the essential criteria for esthetic results in restorations.



Fig. 1 Natural asymmetry.



Fig. 2 Total, unnatural symmetry.

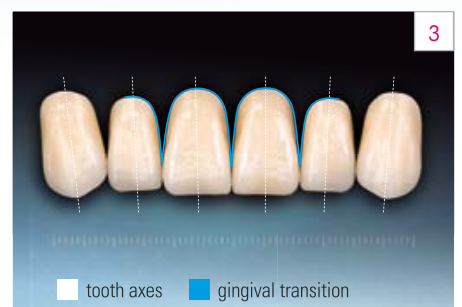

Fig. 3 Features and proportions according to the natural model using the example of VITAPAN EXCELL.

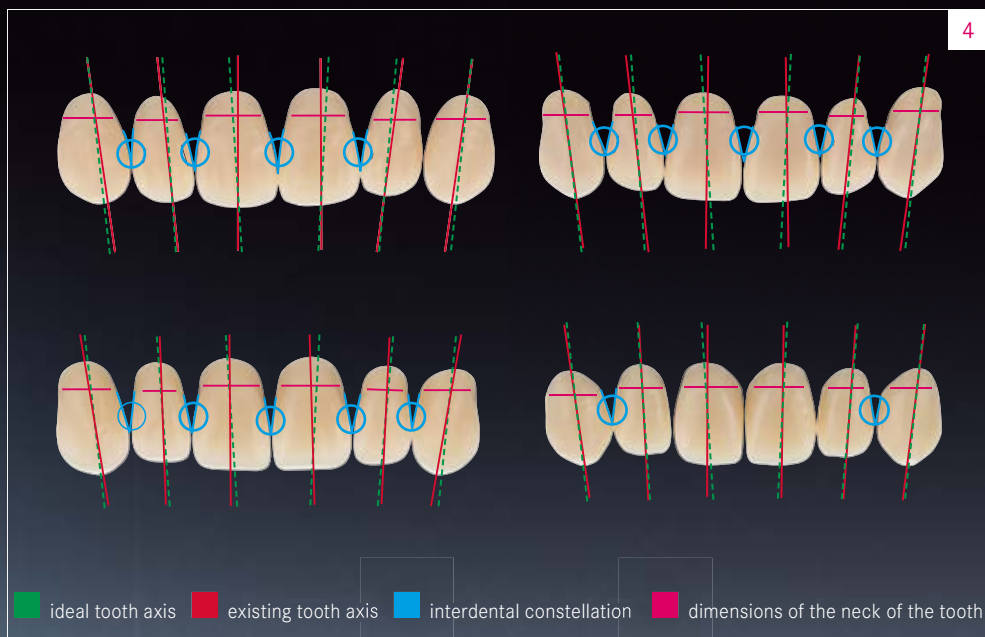


Fig. 4 Tooth features of different selected dental products used as examples. Analysis by expert panel of dental technicians.

Golden proportions and other rules

Since the Renaissance, in the visual arts, pleasing proportions with a well-balanced ratio of length and width have been determined using the "golden proportions." Esthetically pleasing dentures require denture teeth that have not only balanced proportions, but also ideal tooth axes and harmonic curvature and angle features [Fig. 3]. Because esthetic principles have been ignored in the design of teeth, prefabricated teeth in the patient's mouth are often perceived as unnatural despite their functionally correct positioning. We assume that every technician recognizes the following situation from crown and bridge technique: although the finished crown was 100% shade-matched, it shows defects in the axes of the teeth or angular features and is then rejected by the dentist and patient.

"Denture teeth require an ideal tooth axis."

"Esthetic analysis" of prosthetic products

The fact that the industry sometimes fails to pay sufficient attention to esthetic criteria in the development and production of prosthetic teeth is shown by an examination of various prefabricated teeth. It is notable that the tooth design is often mirrored across the quadrants. This means, for instance, that tooth 11 is a mir-

ror image of tooth 21 [Fig. 4]. This results in total symmetry, which causes the resulting teeth to appear unnatural. It was also determined that some prefabricated products have tooth axes [Fig. 4/red], angle features [Fig. 4], and length/width ratios that deviate from the ideal. Poorly designed tooth features complicate the creation of a natural-looking reconstruction of the dentition for the technician. Prefabricated teeth in which the proximal interdental marginal ridges are missing [Fig. 4/blue] hardly allow a natural design of the papilla. Finally, some prefabricated products have the disadvantage of a crown that is clearly separate from the neck of the tooth, which makes it difficult for the technician to create a natural-looking restoration [Fig. 5, 6].

Teeth with "golden proportions"

The new generation of anterior denture teeth, VITAPAN EXCELL, and the tooth line VITA PHYSIODENS, were designed with the esthetic principles of golden proportions."This supports the dental technician in the natural tooth setup and design of the prosthetic base [Fig. 7], and the prostheses look significantly more natural and esthetic, thanks to ideally designed tooth features [Fig. 8, 9].



Fig. 5 VITAPAN EXCELL with a more natural cervical design.

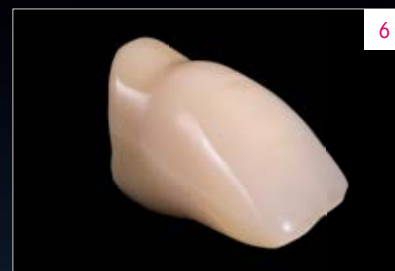

Fig. 6 SR VIVODENT DCL with clearly separate neck of the tooth.

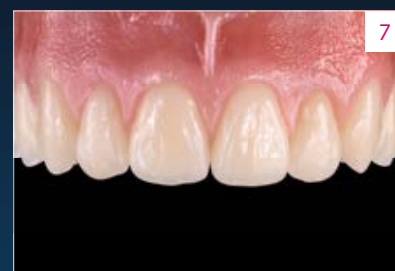

Fig. 7 Natural gingiva design with VITA PHYSIODENS.

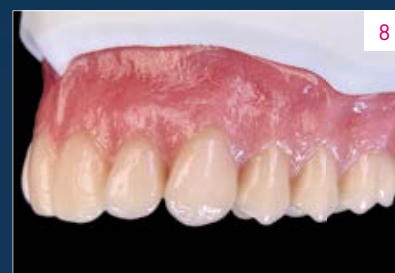

Fig. 8 Proximal interdental margins allow the proper design of the papilla.

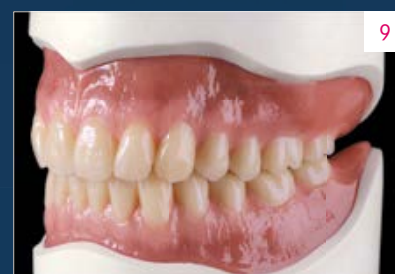

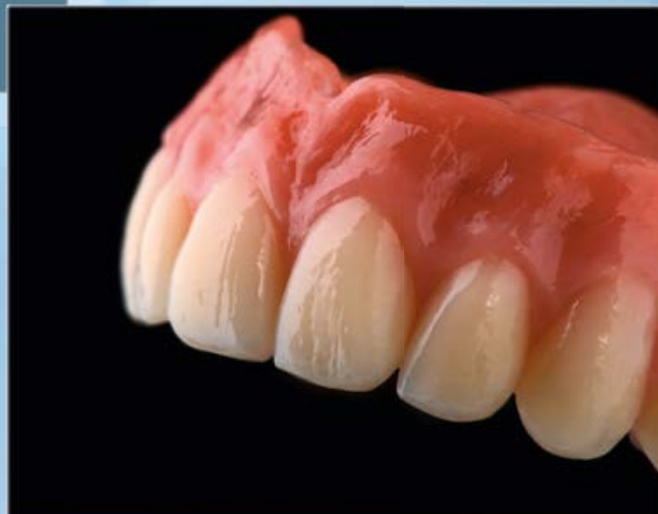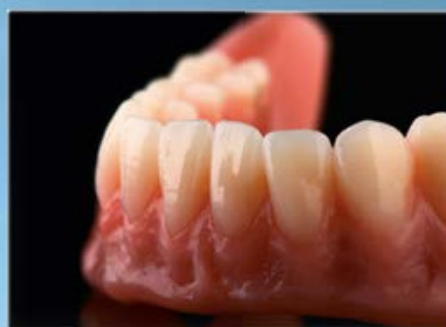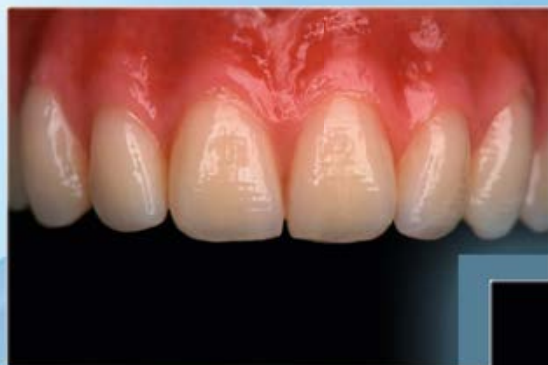Fig. 9 Correct vertical curvature features allow a natural transition from the alveolar / juga alveolaris process, over the marginal periodontium, to the actual tooth

Image sources:

1 – 7 VITA Zahnfabrik, 8 – 9 Viktor Fürgut, Dental Technician.

VITAPAN EXCELL: Proven by numerous technicians all over the world

Prior to the market introduction in March 2017, the new VITAPAN EXCELL anterior teeth (VITA Zahnfabrik, Bad Säckingen, Germany) were tested in numerous laboratories all over the world. Conrad Frerichs, Master Dental Technician (Oldenburg, Germany), Franz Hoppe, Master Dental Technician (Saerbeck, Germany), and Benjamin Strasser, Dental Technician (Regensburg, Germany) had the chance as some of the first technicians, to work with VITAPAN EXCELL. In the following interview, you will find out what esthetic potential the new denture teeth have and how they have proven their worth in daily laboratory work.



Modern denture teeth require natural shapes, good light transmission and vibrant shade play .

Image source:

VITAPAN EXCELL prosthesis by Franz Hoppe, Master Dental Technician, Saerbeck, Germany; photo documentation by Marita Heeren, Oldenburg, Germany.



*Conrad Frerichs, Master
Dental Technician and
Managing Director
Oldenburg, Germany
(PKC Dental-Labor)*

DV: Mr. Frerichs, what criteria does a modern dental prosthesis have to meet from your point of view?

Conrad Frerichs: It must provide a balanced overall composition in terms of esthetic criteria, such as natural shapes, good light transmission, lively shade play, etc. In addition, it must also be compatible with the various modern composites and veneering materials.

DV: What do you think of the shape of the VITAPAN EXCELL?

Conrad Frerichs: The new anterior tooth is very beautifully shaped. Among other things, we are impressed by the harmonious length/width ratio. The body of the tooth appears less voluminous than the VITA PHYSIODENS, for example.

DV: What are the advantages of the unique layered structure of the new denture tooth?

Conrad Frerichs: The layered structure of the new denture tooth is characterized by a balanced light transmission - translucent enough for a lively appearance and at the same time sufficiently masking for use in combination prosthetics.



*Benjamin Strasser,
Dental Technician
Regensburg, Germany
(Donau-Dental
Zahnlaboratorium)*

DV: Mr. Strasser, what can you tell us about the shade play and play of light of the new denture tooth?

Benjamin Strasser: The layering of the denture tooth follows the shade gradient of natural teeth and has a three-dimensional structure. Combined with the multifaceted surface texture, this produces an outstanding play of light.

DV: How does the new denture tooth lend itself to processing and polishing?

Benjamin Strasser: In my experience, the tooth is easy to grind and polish. The material is homogeneous - not too soft for polishing - and the processed result has excellent edge stability. This makes for efficient processing.

DV: What are the best applications for VITAPAN EXCELL?

Benjamin Strasser: It is generally suitable for all prosthetic restorations. Personally, I have come to value the new line of teeth for the production of customized restorations, especially for combination work.



*Franz Hoppe, Master
Dental Technician
Saerbeck, Germany
(Dental Labor Kock)*

DV: Mr. Hoppe, how would you assess the shade accuracy of VITAPAN EXCELL with respect to the VITA Classical Shades?

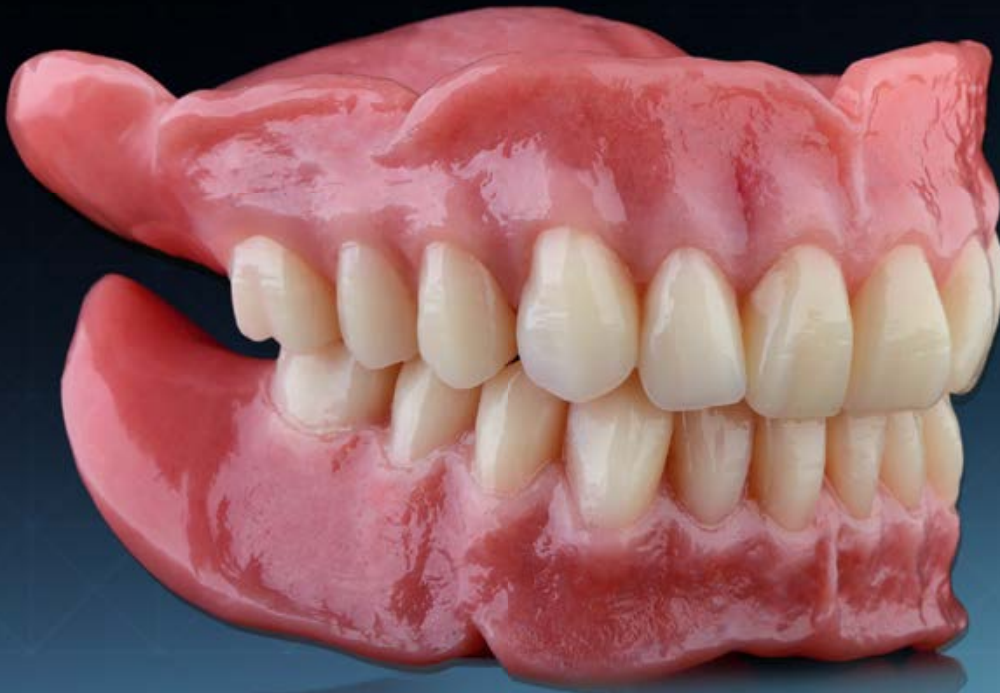Franz Hoppe: With VITAPAN EXCELL a ready-to-use tooth has been developed which has very good shade accuracy on the VITA shade scale. In this case, VITA Zahnfabrik has analyzed many suggestions from practitioners and implemented them correctly.

DV: What kind of feedback have you received on this new generation of anterior denture tooth?

Franz Hoppe: I received very positive feedback after the first trial from a patient who had previously been fitted with "traditional" prostheses with a less pronounced surface texture. He and his dentist were really enthusiastic about how natural the new anterior tooth looked.

DV: How does VITAPAN EXCELL complement the VITA range of teeth?

Franz Hoppe: The new denture tooth is the perfect addition to the VITA product range and gives dental technicians more freedom of choice. VITAPAN EXCELL bridges the gap between the highly translucent VITAPAN PLUS anterior teeth and the customized, accurate shapes of the VITA PHYSIODENS. With VITA, I am now able to find the right set of teeth for each patient, based on shape, shade and surface.

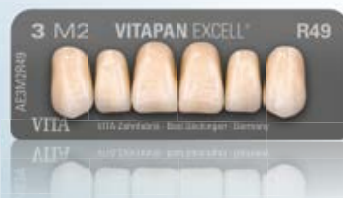

With VITAPAN EXCELL, prosthetic restorations appear especially natural.

Image source: VITAPAN EXCELL prosthesis by Franz Hoppe, Master Dental Technician, Saerbeck, Germany; photo documentation by Marita Heeren, Oldenburg, Germany.

INFO: WHAT IS VITAPAN EXCELL?

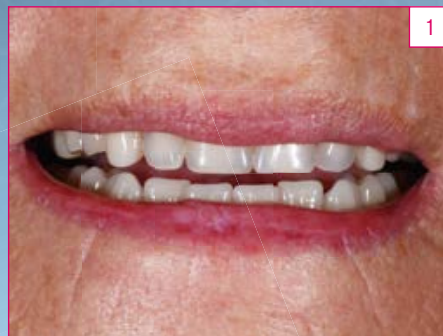VITAPAN EXCELL is a new generation of MRP composite anterior tooth that boasts a brilliant play of shape, shade and light for natural-looking prosthetics. It is perfect for highly esthetic full, partial and implant-retained dentures. VITAPAN EXCELL makes it easy to replicate natural symmetry, thanks to shapes with a balanced length-width ratio, and a convenient reproduction



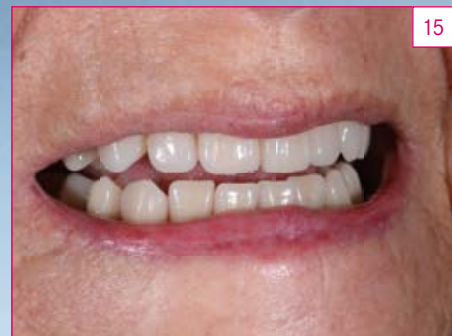of the tooth position with anterior teeth that include ideally aligned tooth axes

VITAPAN EXCELL: For predictable, esthetic and functional results

For predictable and functional esthetic results in restorations, in addition to dental technology experience, we need a denture tooth designed on the basis of the esthetic and functional standards set by nature. VITAPAN EXCELL (VITA Zahnfabrik, Bad Säckingen, Germany) is an example of this kind of anterior tooth, which is characterized by vibrant shapes with "golden proportions." Tooth axes, the length/width ratio and angle characteristics are consistently patterned after nature. In addition, its special layered structure enables a natural play of shade. In the following case report, Darius Northey, Dental Technician (Buderim, Australia) shows how he was able to successfully use the new denture tooth for an implant-supported restoration.



→ **INITIAL SITUATION:** The old, insufficient restorations showed a midline displacement to the right and functional disharmonies. The teeth were abraded, stained and dull.



→ **RESULT:** The patient was very happy with the naturalness of the new restoration.



*Darius Northey,
Dental Technician
Buderim, Australia*

1. Initial clinical situation

A 78-year-old female patient was dissatisfied with the positional stability of her mandibular prosthesis. The acrylic teeth appeared abraded, stained and very dull. After the consultation, the patient decided on two implants in the mandibular in order to achieve greater functional stability, and was referred to an oral surgeon. After a healing period of three months, the implants were osseointegrated in the incisal region of the

mandibular. First, the patient did not want a new total prosthesis in the maxilla, although the midline was shifted extremely to the right and functional disadvantages due to the well-worn and irregular occlusion were to be expected. She feared that her usual appearance would be altered by a new restoration. However, following a comprehensive consultation, she finally opted for a new restoration.

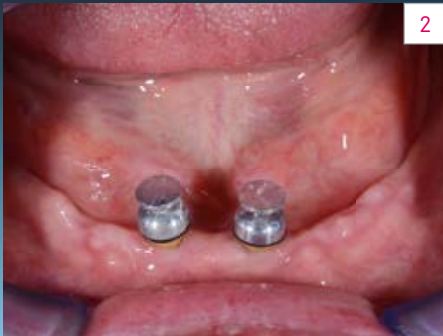

Fig. 2 Two implants were inserted in the incisal region to functionally stabilize the restoration in the mandibular.

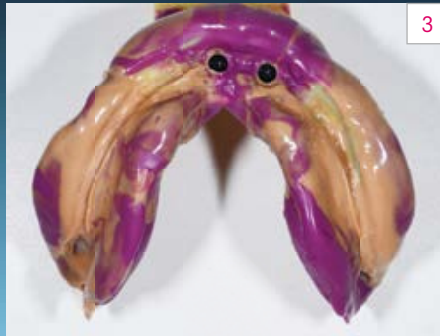

Fig. 3 A custom-made tray was used in the mandibular for a mucodynamic fixation impression.

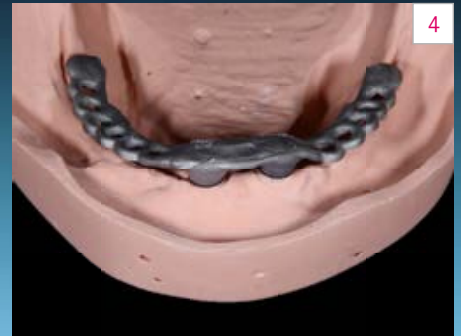

Fig. 4 A simple bar construction was poured and fixed with synthetic material to the abutments.

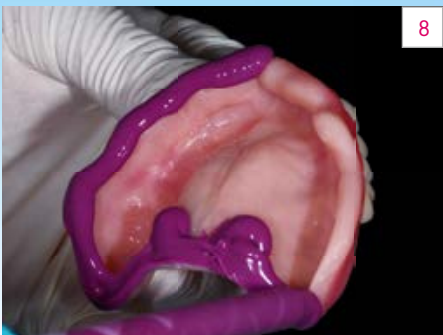

Fig. 8 After the try-in, a mucodynamic impression with setup was taken in the maxilla.

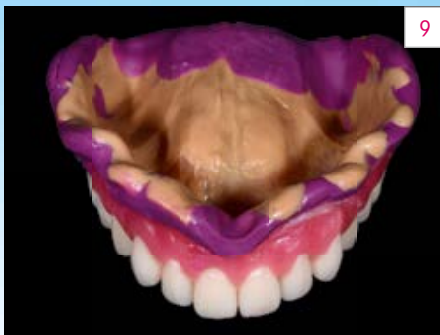

Fig. 9 The final occlusion-adjusted, mucodynamic impression in the duplicated denture base.

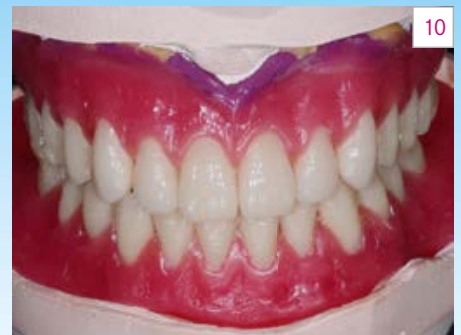

Fig. 10 Based on the bite registration of the setups, the maxilla could be accurately rearticulated.

2. First steps towards restoration

The restoration in the mandible began with an anatomical alginate impression. So that it could be oriented to the old maxillary prosthesis using the "Copy Denture" technique, this was duplicated with putty and reproduced with a cold polymer for denture bases. For the mandible, a custom-made impression tray was made, a mucodynamic impression was taken in several steps and the impression cap was affixed. Using the model, a simple bar construction was fabricated and affixed with synthetic material to the attachments. A wax

rim was created over the bar in the mandible, and plates for the imaging of the gothic arch positioned on this and the maxillary duplicate. Laterotrusion, protrusion and centric were recorded and affixed. The duplicate was successively reduced in the setup area in order to first position and try in the VITAPAN EXCELL anterior tooth and then the VITAPAN LINGOFORM posterior tooth.

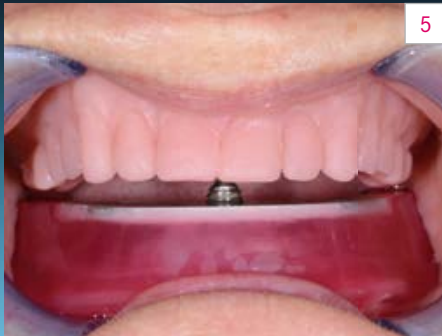

Fig. 5 The centric and temporomandibular movements were recorded with the gothic arch.

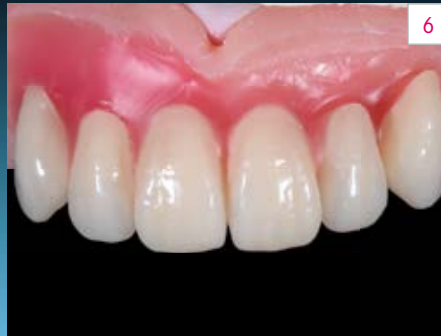

Fig. 6 First, the esthetic zone of the maxillary duplicate was reduced, then replaced with VITAPAN EXCELL, and finally tried in.

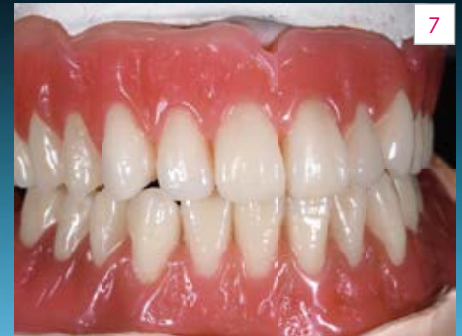

Fig. 7 The final wax setup in the articulator with molded gingival anatomy before the try-in.

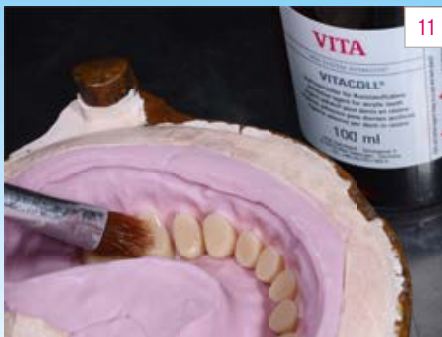

Fig. 11 VITAPAN EXCELL and LINGOFORM were conditioned with VITACOLL to ensure good adhesion to the base.

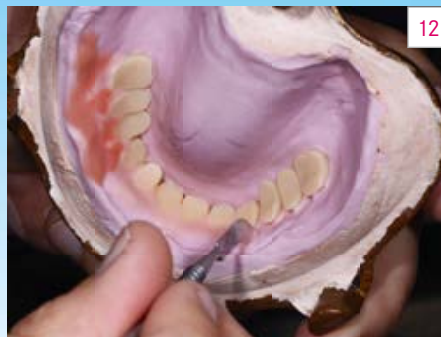

Fig. 12 The vestibular plate was customized with several synthetic material layers in different gingival shades.

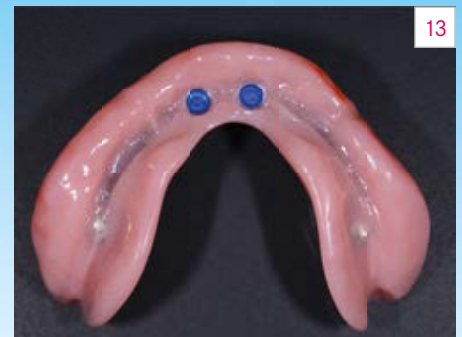

Fig. 13 The bridge and attachments were integrated by polymerization of the synthetic material base.

3. Prostheses fabrication and finalization

After complete functional and esthetic try-in, a mucodynamic impression with wax setup on a duplicate base was taken in the maxilla. The bite was registered with silicon. In the maxilla, a final master model was produced and articulated according to the vertical dimension. The maxilla and mandibular setups were embedded in cuvettes, boiled out and pressed with heat-curing polymer into different gingival shades. After polymerization, both works were rearticulated and an occlusion check done. The prostheses were processed with fine-cut

carbide milling tools and rubber polishers. The final polishing was done with pumice and polishing paste, as well as a buffing wheel. The patient was very satisfied with the functional and esthetic result. Thanks to the lifelike shapes with "golden proportions," the three-dimensional anatomically layered construction and the multifaceted surface texture, the prosthetic restoration with VITAPAN EXCELL appears very natural.

Report 07/17

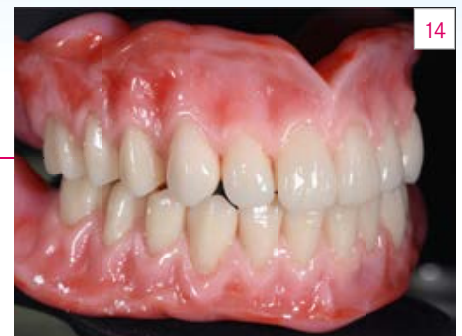
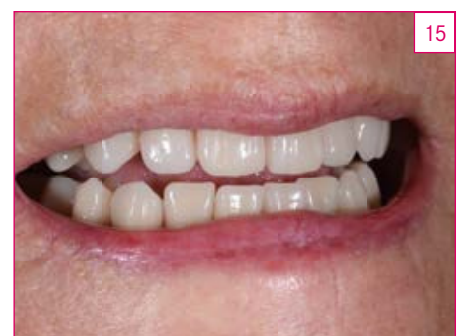
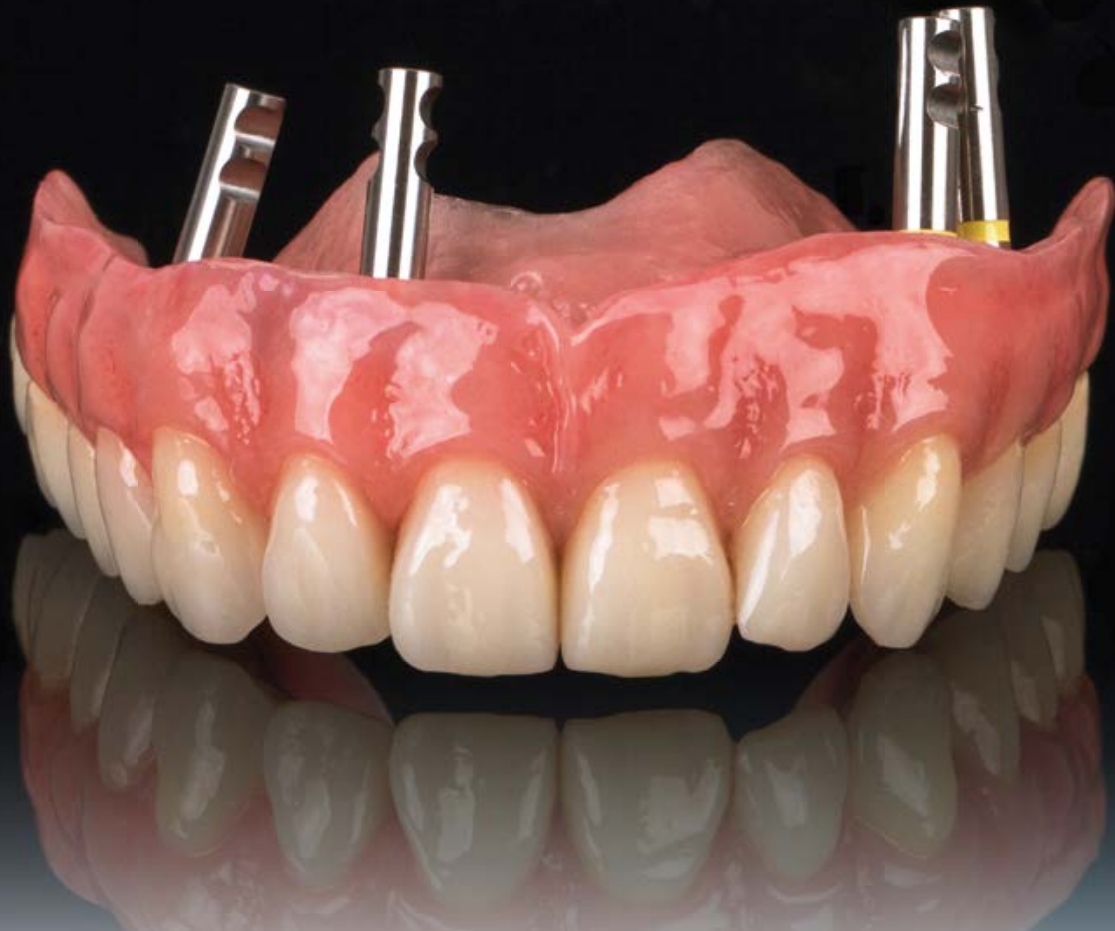Fig. 14 The finished restorations after elaboration and polishing in static occlusion.




RESULT: The patient was very happy with the naturalness of the new restoration.



Implant-supported restoration with VITA anterior teeth made of MRP composite

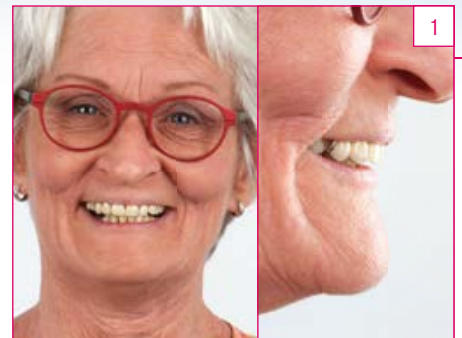

*Carolin Wehning, Dental Technician
Bocholt, Germany*



*Dr. med. dent. Babak Varzideh
Bocholt, Germany*

Removable, implant-supported restorations are often the solution in unfavorable anatomical conditions, as they ensure good functional stability, even in a case like this one. A central prerequisite for durable implant-supported dentures is wear-resistant denture teeth since strong chewing forces usually occur here. VITAPAN EXCELL anterior teeth (VITA Zahnfabrik, Bad Säckingen, Germany) are fabricated from particularly abrasion-resistant MRP composite material. In their report, Carolin Wehning, Dental Technician, and Dr. Babak Varzideh (Bocholt, Germany) explain how this new generation of anterior teeth with "golden proportions" has been proven in the production of an implant-supported maxillary prosthesis



➔ **INITIAL SITUATION:** Esthetically and functionally insufficient initial situation in the maxilla. The strong distal occlusion position was to be compensated for in the new fabrication.

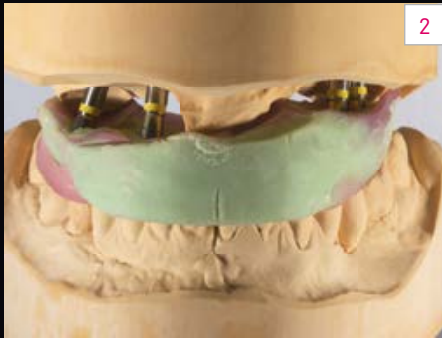

Fig. 2 An implant-supported bite registration enabled the precise articulation of the two master models.

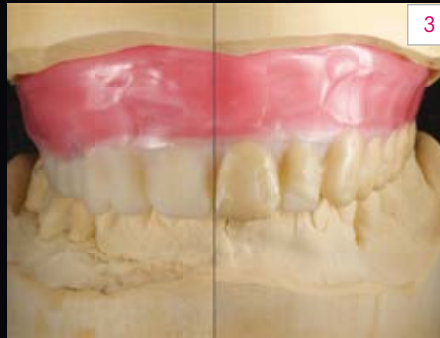

Fig. 3 A wax-up was done on a synthetic duplicate of the dental arch of the old prosthesis to define the new target situation.

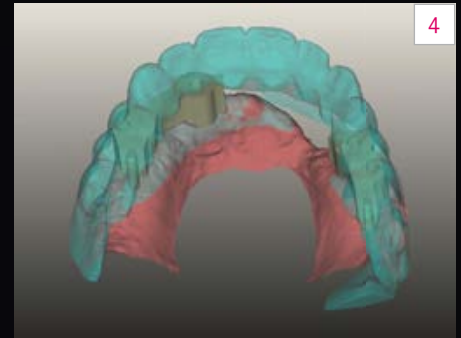


Fig. 4 The new setup was scanned in and the primary, secondary and tertiary frameworks designed in keeping with the dimensions.



Fig. 5 The primary structure of zirconia was milled in parallel on the capped model. The friction surfaces should be 4 to 5 millimeters.

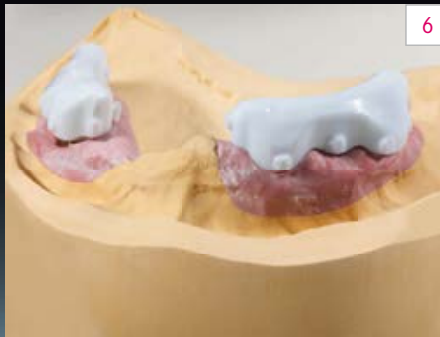

Fig. 6 Secondary components were milled for the try-in of the setup and friction control out of PMMA so that the final components could later be implemented in PEEK using CAD/CAM.



Fig. 7 The wax try-in revealed the need for optimization.

1. Initial findings and implantation

A 56-year-old female patient presented in the dental practice because she was dissatisfied with her removable, implant-retained maxillary prosthesis from a functional and esthetic point of view. The implants were placed unfavorably with regard to the insertion direction and exhibit the III degree of mobility, due to the uneven stress. The patient wanted to be able to show a natural-looking, individual smile again. The new restoration was also designed to enable reliable wearing comfort during eating, as well as simple cleaning. The pronounced distal occlusion position was to be compensated for with the new dentures. After extensive consultation, the patient decided on bridgework on four strategically placed implants. The existing implants were explanted, and four new pillars were placed in regions 14, 11, 24 and 25, in keeping with the planned prosthetic.

2. Impression and wax setup

After a healing period of seven months, an open impression was taken of the situation. On the master model, a bite registration was produced from light-curing synthetic material, which was supported by the screwed-on healing caps and was lined with silicone. The occlusal situation and the midline were precisely transferred to the articulator. The dental arch of the old maxillary prosthesis was duplicated using synthetic material. The tooth shape and occlusion with the mandible were optimized, per the wax-up and the prosthetic base was designed from pink baseplate wax. This setup was scanned in and provided planning security during the design process of the primary (zirconia), secondary (PEEK) and tertiary frameworks (chromium-cobalt-molybdenum). The wax setup with VITAPAN EXCELL denture teeth in the esthetic zone was then done on the tertiary framework. The solidity of the anterior teeth helped balance the distal occlusion position.

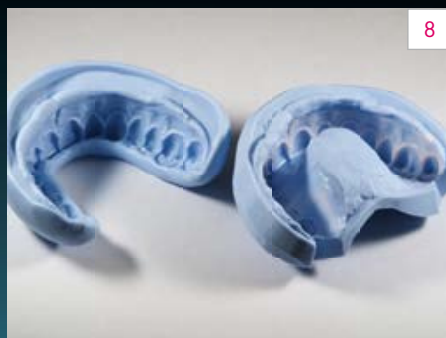

Fig. 8 Detailed silicone rims for checking (left) and detailed implementation with whitish VITAFOL H (right).

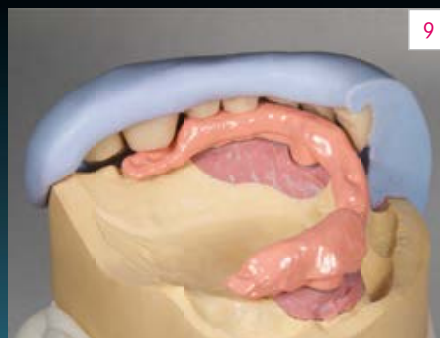

Fig. 9 Last position control: The tertiary framework opaqued with gingiva shades prior to implementation in synthetic material.

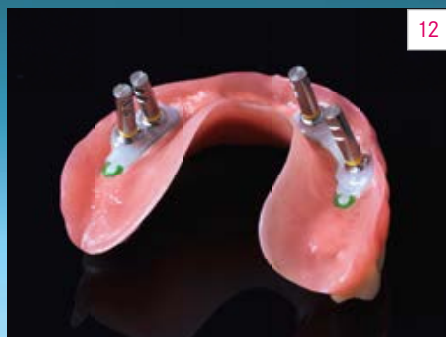

Fig. 12 Primary framework of zirconia with green slide attachment elements and secondary framework of PEEK.

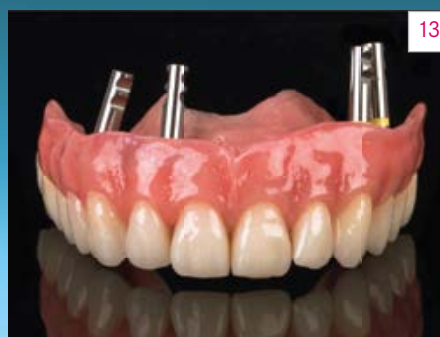

Fig. 13 The highly esthetic final restoration with inserted implant analogs.

3. Finalization and result

Following a successful wax try-in, the maxillary prosthesis of synthetic material was implemented. The silicone key cross-linked with VITAFOL H (silicone film) enabled a detailed reproduction of the gingival surface texture. After only minor elaboration, the vestibular portions of the denture base were sandblasted and moistened with VITA VM LC MODELLING LIQUID. For a particularly natural-looking, vibrant effect, the prosthesis was customized with VITA VM LC flow veneering composite (GINGIVA 1; old pink and GINGIVA 3; pink), as well as VITA VM LC PAINT shades. In combination with the good light dynamics of the VITAPAN EXCELL, a highly esthetic, removable restoration was created step by step. It is important that the denture teeth were ground for the framework structure, but still displayed excellent shade stability.

As a result, the patient was very satisfied with the wearing comfort of the prosthesis and the esthetic appearance achieved. Carolin Wehning's summary: "The new VITAPAN EXCELL anterior tooth has a really beautiful effect in this restoration."

Report 07/17

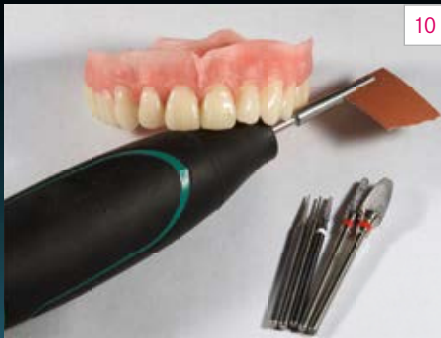

Fig. 10 Due to the detailed reproduction, the processing proceeded rapidly by hand.

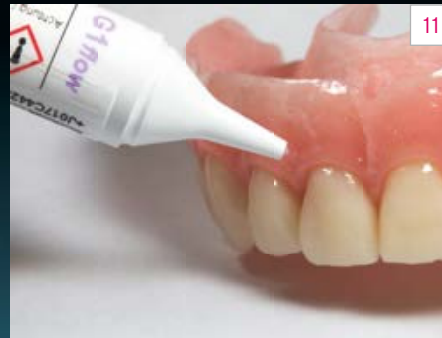
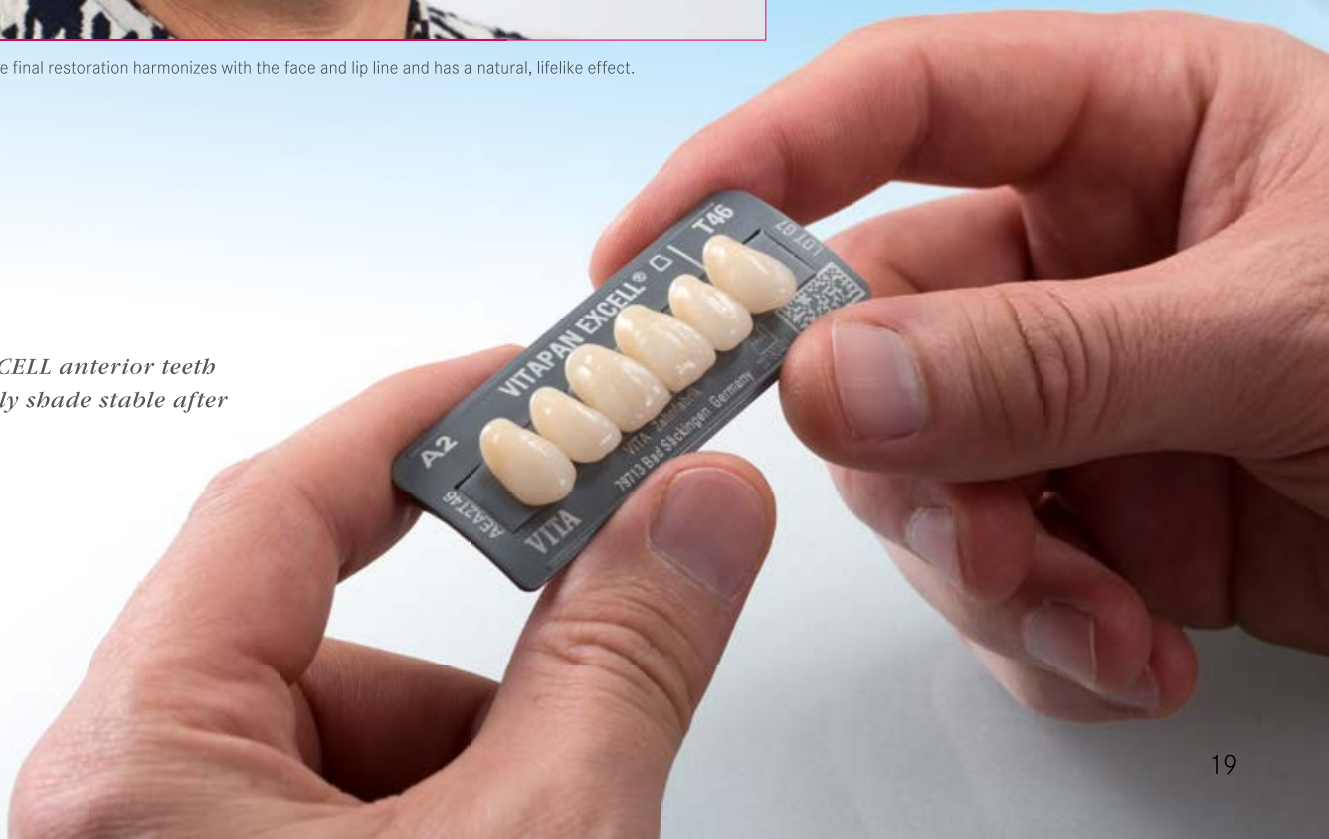
Fig. 11 The vestibular portions of the denture base were customized to a lifelike appearance with VITA VM LC flow.



RESULT: The final restoration harmonizes with the face and lip line and has a natural, lifelike effect.

VITAPAN EXCELL anterior teeth are amazingly shade stable after grinding.



New generation of anterior teeth for a new generation of patients



*Urban Christen, Denturist
Hunzenschwil, Switzerland*

The new generation of active adults have extremely high expectations of restorations. They desire restorations that integrate harmoniously into their external appearance and emphasize their vitality. VITAPAN EXCELL (VITA Zahnfabrik, Bad Säckingen, Germany) is a new generation of anterior teeth that meet a number of significant expectations. The layered construction of this anterior tooth is designed in such a way that it mirrors the natural play of shades. In combination with the multifaceted surface texture, it enables restorations with an especially lifelike play of shade and light. In the following case report, Urban Christen, Denturist (Hunzenschwil, Switzerland) describes the essential steps of a total prosthesis restoration with VITAPAN EXCELL.



➔ **INITIAL SITUATION:** The esthetic appearance shows clear deficits.



Fig. 2 Chewing efficiency and phonetics were not satisfactory.



**1. Initial situation:
insufficient total restoration**

A 51-year-old female patient who was dissatisfied with the esthetic appearance, chewing efficiency and phonetics of her current total denture restoration, presented at my practice. Deficits in the esthetic zone, such as the tapered incisors, which were too prominent vestibular and caudal, were immediately recognizable. It was difficult for the patient to pronounce the letter "F" with this total prosthesis. In addition, the extraoral inspection of the dentures showed significant abrasions on the denture teeth, which over time, had led to a loss of the vertical dimension. After a comprehensive consultation, the patient decided on a completely new fabrication of a total prosthesis.

**2. Precise impression:
For predictable results**

With prefabricated Schreinemakers trays, an initial impression with alginate was taken, in which all relevant anatomical structures were reproduced. Now the individual impression trays and bite templates could be produced on the created models. Before taking the mucodynamic impression, the trays were tried in and shortened, as needed, to ensure a secure fit. On this basis, master models were created on which the bite templates were produced. For reproducible encoding with a registration silicone, retentive elements were incorporated on both sides of the mandibular wax rim, and triangular grooves were used in the maxillary wax rim for clear centric repositioning.

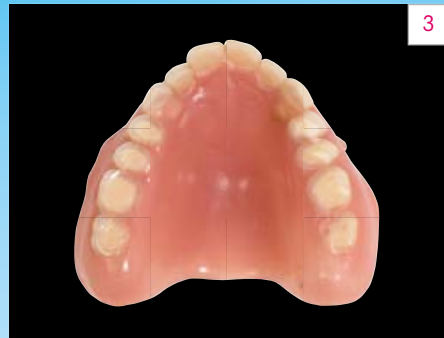

Fig. 3 The esthetically and functionally insufficient prostheses showed massive occlusal abrasions.

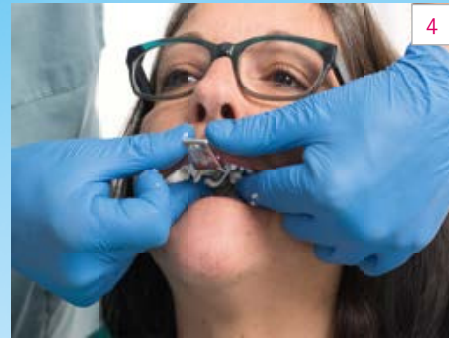


Fig. 4 The alveolar ridges were molded in the maxilla and mandible with prefabricated anatomical trays.

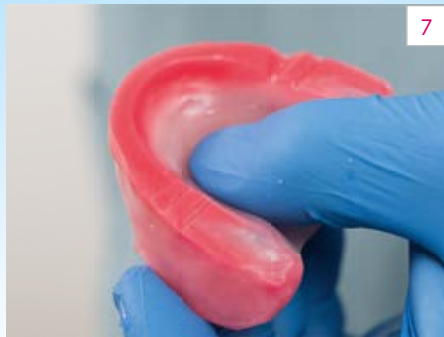

Fig. 7 Triangular grooves in the maxillary bite template allowed for clinical repositioning and testing of the centric.

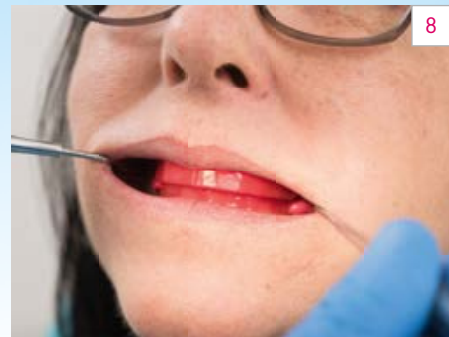

Fig. 8 The centric condylar position was encoded with registration silicone and then checked.

3. Prosthetic result: Esthetic and functional harmony

The setup was based on the registered wax rims. During the setup of the anterior maxilla, attention was paid to a round and wider shape of the dental arch, which also shifted the incisal edges considerably more cranially. Thanks to the balanced length/width ratio of VITAPAN EXCELL, the anterior tooth setup was easily accomplished by hand. In the wax try-in, the denture tooth setup harmonized with the musculature, lip line and physiognomy, and allowed for flawless phonetics. After the implementation in synthetic material, the total denture restoration was very lifelike and natural, particularly with the patient's high smile line. To be able to achieve this result, the layered

construction of VITAPAN EXCELL anterior teeth was designed to mirror the shade play of natural teeth in the form of a three-dimensional structure. In combination with the multifaceted surface texture, this new generation of anterior teeth enable dentures with a lively play of shade and light.

Report 07/17

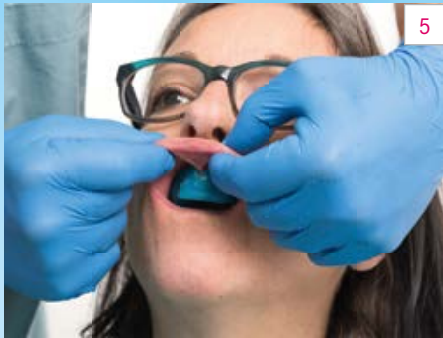


Fig. 5 The position of the individual impression trays must also be guaranteed during mucodynamic movements.

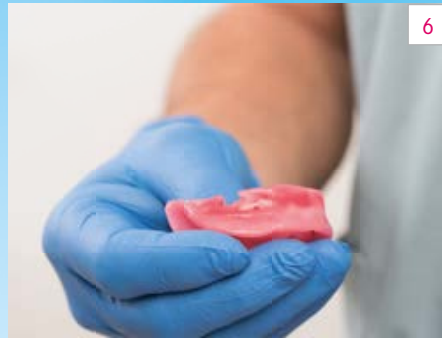

Fig. 6 A retentive undercut was incorporated in the mandibular wax rim to affix the registration silicone.

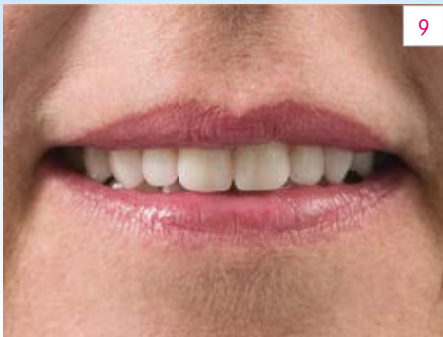

Fig. 9 Since VITAPAN EXCELL is based on the natural model, a quick and individual wax setup is possible.



Fig. 10 The patient was able to pronounce the letter "F" without difficulty with the wax try-in.

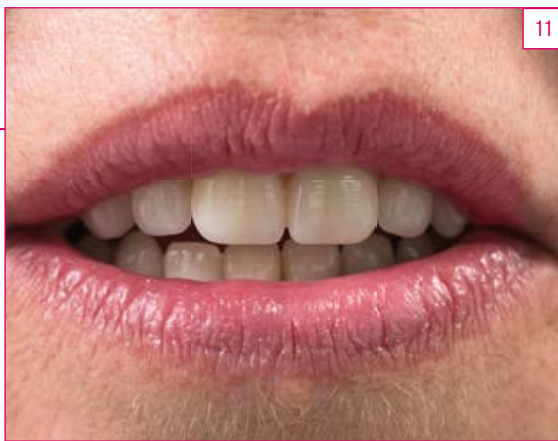

Fig. 11 The three-dimensional, anatomically layered structure, combined with the multifaceted surface texture, allowed a natural play of shade and light.



RESULT: The patient was enthusiastic about the highly esthetic result and the functionality of her new restoration.

Reproduction of the gingiva: Essential steps for customization



*Martina Rosenbusch,
Dental Technician
Bad Säckingen, Germany*

Each gingiva has individual characteristic shades and surface structures. In the total and partial denture restoration of patients with a high smile line, it is particularly important to reproduce the individual characteristics of the gingiva; otherwise, the prosthesis is not harmoniously integrated into the oral appearance. Flowable, light-curing veneering composite allows a rational individualization in these cases. In the following report, Martina Rosenbusch, Dental Technician (Bad Säckingen, Germany) explains how the vestibular labial shield of a prosthesis can be efficiently customized with VITA VM LC flow (VITA Zahnfabrik, Bad Säckingen, Germany).

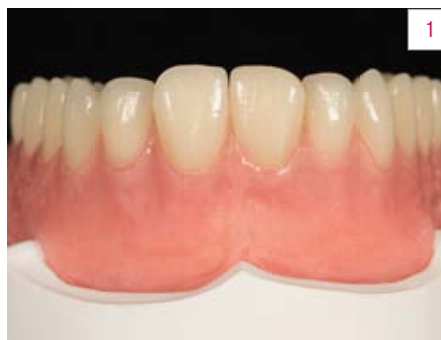

Fig. 1 The vestibular labial shield was roughened with a carbide cutter and sandblasted.

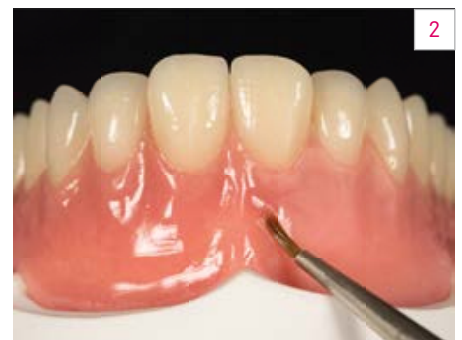
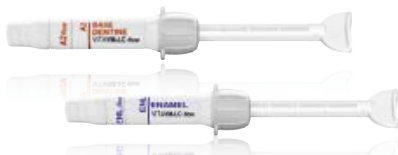
Fig. 2 For a good chemical bond, VITA VM LC MODELLING LIQUID was applied.

1. Basics and conditioning

In the customization of a denture base using the classical filling method, the inlay of various synthetic materials for dentures cannot be extensively controlled. On the other hand, customization with the flowable but stable VITA VM LC flow veneering composite offers the advantage that the material can be applied precisely and in a completed targeted manner. However, prior to customization, the polymerized base must be pretreated. For this purpose, the surfaces are first roughened with a cross-cut carbide bur and then sandblasted with aluminum oxide (50 microns, 2.0 bar). For a good chemical bond, a bonding agent (VITA VM LC MODELING LIQUID) is also applied in the last step for 30 to 60 seconds.



The flowable, light-curing veneering composite VITA VM LC flow is ideally suited for customizing denture bases.

2. Individualization using composite

In this case, customization was done using VITA VM LC flow and the PAINT line of products. To reproduce the alveolar processes in the cervical region, the pink-colored GINGIVA 3 (G3) material was applied underneath. To imitate the underlying, attached gingiva, the light, pastel-colored EFFECT ENAMEL 2 (EE2) was applied. The transition to the free mucosa was designed with dark G4 (brownish red). Afterwards, it was characterized with bluish VM LC PAINT 17 and affixed with translucent WINDOW after intermediate curing to imitate delicate vessel lines. The labial frenulum was finally reconstructed with light G1 (dusky pink). This was followed by final polymerization in the polymerization device with VM LC GEL to avoid an inhibition layer. Since VITA VM LC flow can be applied precisely, no shape corrections were necessary.

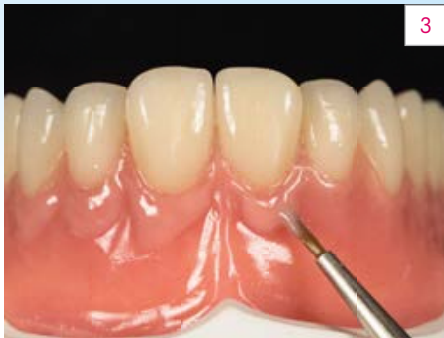

Fig. 3 The stability of the thixotropic veneering composite allows a precise application.

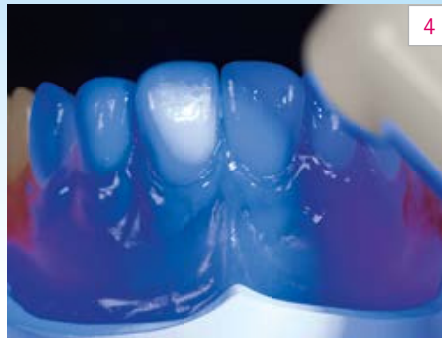

Fig. 4 The individual layers underwent a brief intermediate curing to set the modeling.

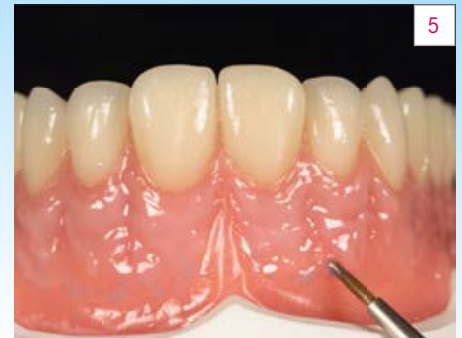

Fig. 5 The transition from attached gingiva to free mucosa was characterized with delicate bluish vessels.

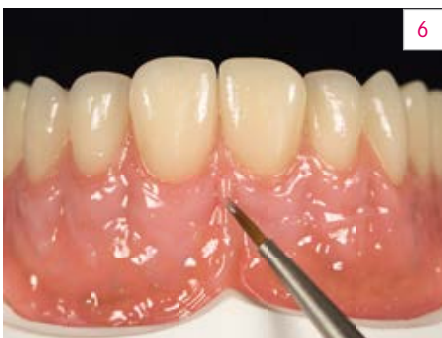

Fig. 6 The labial frenulum was finally reconstructed with brighter VITA VM LC GINGIVA 1.

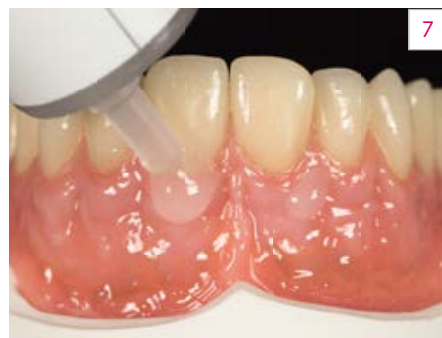

Fig. 7 Prior to the final curing, VITA VM LC GEL was applied to prevent an oxygen inhibition layer.

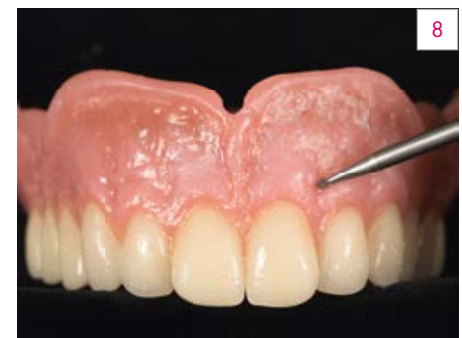
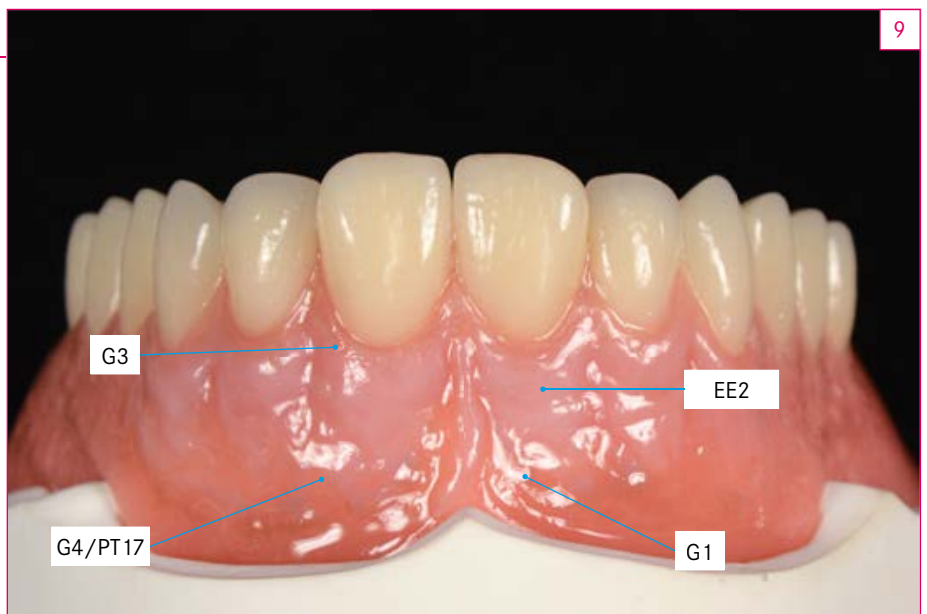
Fig. 8 A surface texture was incorporated before polishing with the stippling instrument.

3. Finalization and final result

Before the final polishing, texture was incorporated with the stippling instrument. Then the polishing was done with silicone polishers, goat hair brush, wool swab, felt wheel and suitable polishing pastes. With the procedure described here, the gingiva can be faithfully reproduced within 30 to 40 minutes. As a result, the individualized maxillary prosthesis with VITAPAN EXCELL anterior teeth makes a strong impression with its balanced harmony in red-white esthetics.

Report 07/17



➔ **RESULT:** The natural gingival portions were efficiently reconstructed. The final result shows the harmony between the red and white esthetic.

Basics of digital prosthetic fabrication



Falko Noack, Engineer (FH)
Koblach, Austria

The Ceramill Full Denture System (Amann Girrbach AG, Koblach, Austria) enables an efficient, precise CAD/CAM-supported denture fabrication. With VITA VIONIC SOLUTIONS (VITA Zahnfabrik, Bad Säckingen, Germany), there is now the right material system for every process step of digital production. Thanks to the combination of intelligent manufacturing technology and coordinated materials, laboratories can increase their productivity in prosthetics. With the Ceramill Mind software, VITA denture teeth can be used to create digital setups in more than 300 functional variants. Falko Noack, Engineer (Head of Application Technology R&D Amann Girrbach AG, Koblach, Austria) answers questions about the digital workflow and its advantages.

DV: What must be considered in the digital workflow in order to achieve a good end result?

Falko Noack, Engineer: Here, the same principles apply as in the manual process - if the working base does not fit, the final result will also show deficits. The most relevant step is not with the dental technician, but with the dentist. Digital total prosthetics require proper functional impressions to produce adequate models and an accurate bite registration.

DV: What options are offered by the Ceramill Mind software for denture setup?

Falko Noack, Engineer: In principle, with VITA denture teeth and the Ceramill Mind software, patient-specific denture settings can be created in more than 300 functional variants. In the front, the software allows individual positioning of each individual tooth. In the posterior region, the virtual alignment is done according to the specifications of digital model analysis. However, the modification of the digitally setup posterior teeth, can only be done in conjunction with opposing quadrants, to ensure that ideal occlusion relationships are guaranteed at all times.

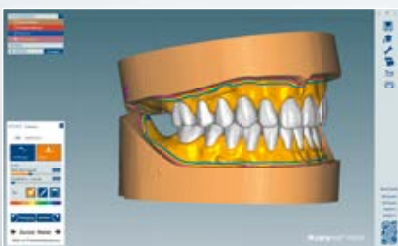


Fig. 1 Example of CAD prosthesis design using Ceramill Mind-Software.



Fig. 2 VITA VIONIC FRAME denture framework solution with VITA denture teeth are stably embedded in wax.



Fig. 3 The CAM-processing of the denture teeth is done similarly to the basal and circular construction.

"With Ceramill FDS and VITA VIONIC, there are more than 300 functional variants that can be digitally implemented."

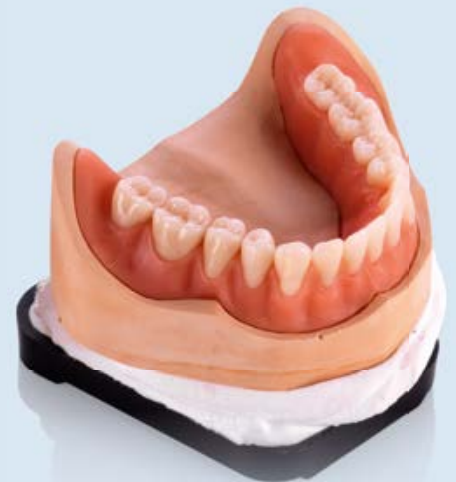
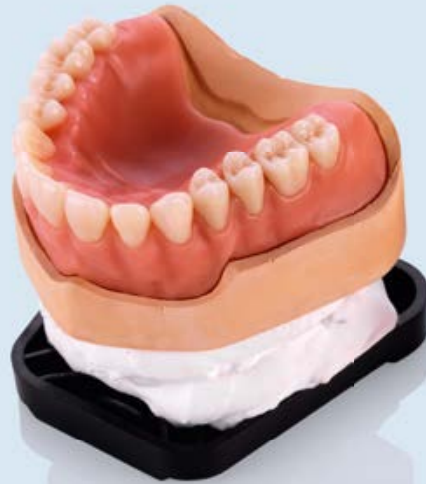
Fig. 7 The simple and safe bonding enables a very efficient fabrication of the prostheses.

DV: What possibilities do technicians have for the setup and designing of the gingiva?

Falko Noack, Engineer: For VITA VIONIC SOLUTIONS, laboratories have a choice between buccal and lingual concepts when designing with Ceramill Mind - depending on the anatomical situation and/or the desired philosophy. In addition, in terms of the occlusal position, the software supports the cross bite, as well as the normal bite. Ceramill Mind offers digital design tools, such as the free-form function of the wizard, for the individual design of the gingival portions.

DV: How is the try-in done with VITA VIONIC SOLUTIONS and Ceramill FDS?

Falko Noack, Engineer: For the clinical wax try-in, there are tooth and gingiva-colored VITA VIONIC WAX blanks. The laboratory can either mill a full-sized wax try-in from a tooth-colored blank, or produce the base from

gingiva-colored blanks and affix the CAM-modified denture teeth in the milled alveoli. If the wax try-in was in full-size, then the CAM modification takes place only on completion.

DV: How is the final completion done, and what components are needed?

Falko Noack, Engineer: After a successful try-in, the final denture base is milled using Ceramill Motion 2 from a PMMA blank. For this, the VITA VIONIC System offers VITA VIONIC BASE blanks in different gingiva shades. With the VITA VIONIC FRAME prosthetic frame solution, the CAM-supported basal and circular modification of the denture teeth can be "semi-automated," according to the digital prosthetic design. This ensures a precise fit of the denture teeth to the milled alveoli. Adhesive fixation of the denture teeth in the alveoli of the base is then performed with the VITA VIONIC BOND fixation system.

DV: What are the advantages of digital prostheses with regard to precision and fabrication time?

Falko Noack, Engineer: The factory system settings automatically provide correct occlusion and are very user-friendly. This results in increased precision and reduced time. In particular, the digital tooth setup allows a time savings of up to 60 percent compared to manual installation. By milling the wax or synthetic base, wax contraction or polymerization shrinkage are eliminated as sources of error.

Report 07/17

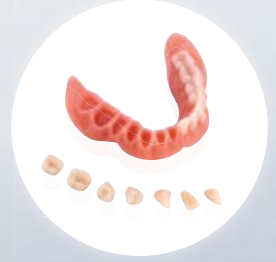
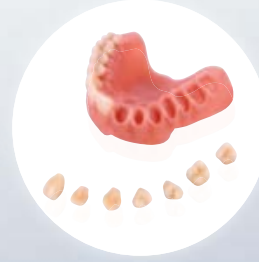
Fig. 4 The final milled PMMA base after successful wax try-in.

Fig. 5 The fit of the milled base is absolutely precise since there is no polymerization shrinkage.

Fig. 6 CAM-modified denture teeth exhibit a high accuracy of fit to the alveoli of the base.



*Karl-Heinz Körholz, Dental Technician
Königswinter-Vinxel, Germany*

In March 2017, a coordinated material system for process-reliable CAD/CAM denture fabrication was presented for the first time with VITA VIONIC SOLUTIONS (VITA Zahnfabrik, Bad Säckingen, Germany). The system includes wax and PMMA blanks for the fabrication of wax try-ins and final denture bases, special prosthetic frameworks for CAM processing of denture teeth, and a bonding solution for the adhesive fixation of ready-to-use teeth in the milled bases. In conjunction with intelligent CAD/CAM solutions like Ceramill FDS, prosthetics can be fabricated almost at the "push of a button." In this article, Karl-Heinz Körholz, Dental Technician (Königswinter-Vinxel, Germany) describes the digital workflow step-by-step.

VITA VIONIC SOLUTIONS: Denture fabrication at the touch of a button

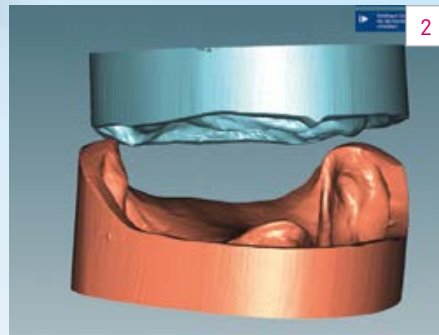


Fig. 2 The digitalized model in the clinically determined vertical dimension.

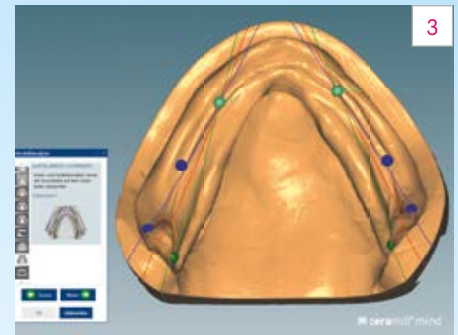


Fig. 3 The model analysis was conducted with the Ceramill Mind Software according to Tif.



INITIAL SITUATION: The mandible model before digitalization with the laboratory scanner.

1. Assessment

A 75-year-old, female patient presented with wearing discomfort and was dissatisfied with the esthetic appearance of her total prosthetic. The alveolar ridge in the mandible was clearly compromised and pointed. The area of the incisors was already absorbed at the mouth base level. Conditions were similar in the maxilla - in the first quadrant, the partially impacted tooth 18 had broken through diagonally with the occlusal surface in the vestibular direction. Following a comprehensive consultation, the patient decided on a new fabrication. We decided to fabricate the prosthetic using the digital procedure.

2. Impression, bite registration and scan

"The anatomical impressions, relational templates and functional models must be precise! If these steps are not well prepared, you should not go into the digital workflow," says Körholz. Otherwise, the initial mistakes would continue throughout the entire process and impact the final restoration. In this case, after the impression taking, model fabrication and relation determination, both functional models were individually scanned, and then the vertical dimension was digitized using the articulated models and the bite templates

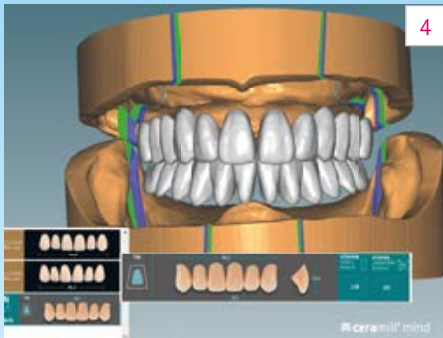


Fig. 4 The virtual setup was performed by pushing a button after the tooth selection.

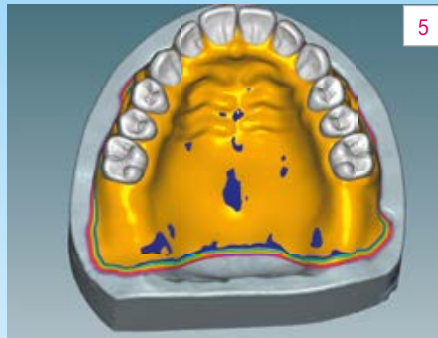


Fig. 5 Functional margins and dimensioning of the denture base were digitally designed.

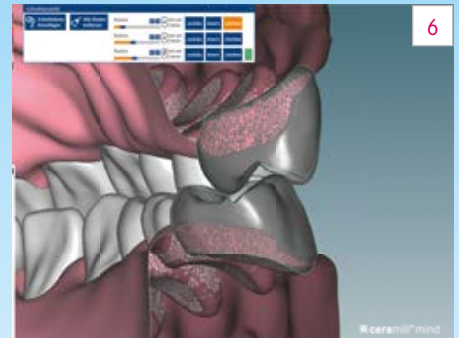


Fig. 6 Cross-sectional view of the ideal dentition in the molar area.

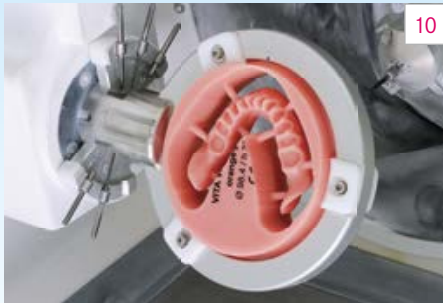

Fig. 10 The denture base was fabricated from the PMMA blank VITA VIONIC BASE.

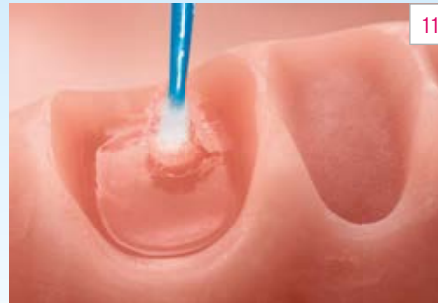

Fig. 11 The milled PMMA alveoli were moistened with VITA VIONIC BOND ...

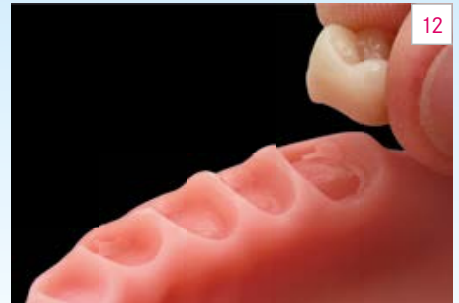
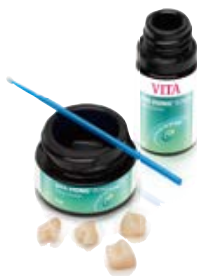
Fig. 12 ... and the dislodged basal teeth bonded with adhesive, accurately fitting, in the cavity.

3. Model analysis, construction and try-in



VITA VIONIC BOND is an efficient adhesive bonding system for VITA denture teeth.

For a functional determination of the setup, a digital model analysis according to T/F was carried out with the Ceramill Mind software. "After selecting the teeth, all I had to do was press the enter button and the denture teeth were set up virtually," said Körholz when describing the process. The denture base can be individually designed as needed with the design tools. In the current case, there was a slight, virtual individualization of the maxillary anterior. The denture was then fully milled from the tooth-shaded VITA VIONIC WAX blank (shade: white) for the clinical try-in. "With this important intermediate step, functionality and esthetics can be controlled once again. This

includes, among other things, whether the occlusal plane and midline integrate harmoniously into the overall oral picture," explains Körholz. In addition, the try-in also allows the control of phonetics.

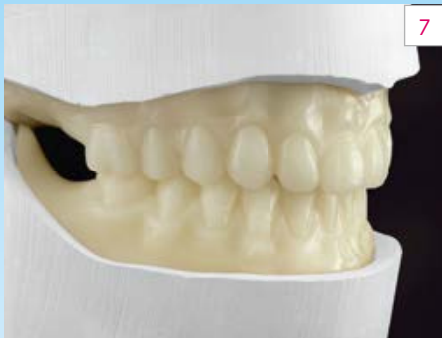

Fig. 7 Midline, occlusion level and phonetics were checked using a wax try-in.

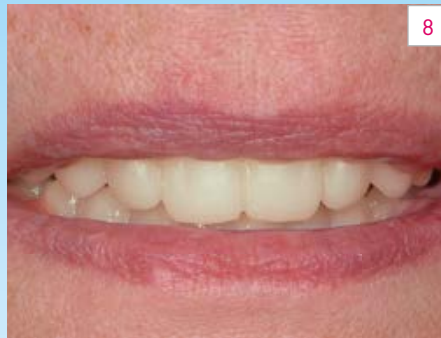

Fig. 8 The CAD/CAM-fabricated wax try-in made of VITA VIONIC WAX white in the patient's mouth.



Fig. 9 The teeth in the VITA VIONIC FRAME were modified circularly and basally.

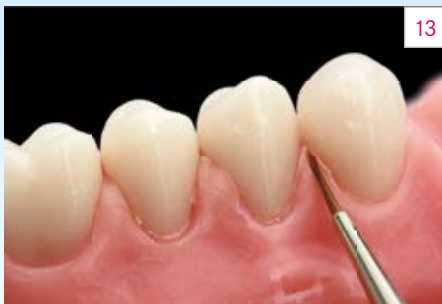

Fig. 13 Closing of the interdental spaces with veneering composite VITA VM LC flow.

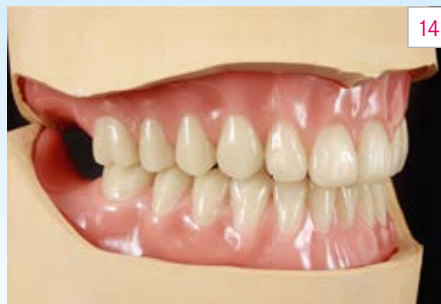

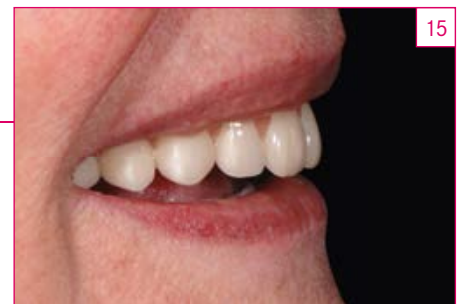Fig. 14 After polymerization in the pressure pot, the final polishing is done.

4. Denture fabrication and finalization

Following successful verification of all parameters, the circular and basal CAM modification of the VITAPAN EXCELL DD FRAME anterior teeth and the VITAPAN LINGOFORM DD FRAME posterior teeth was performed with the Ceramill Motion 2 system, similar to the CAD planning. In addition, the final denture base was milled from a VITA VIONIC BASE PMMA blank. "This makes the CAM machine perfect! As a result, the denture teeth fit precisely into the milled alveoli of the base - like two Lego bricks that fit together perfectly," explains Körholz. After conditioning of the base and denture teeth, the anterior and posterior teeth were bonded adhesively in the milled

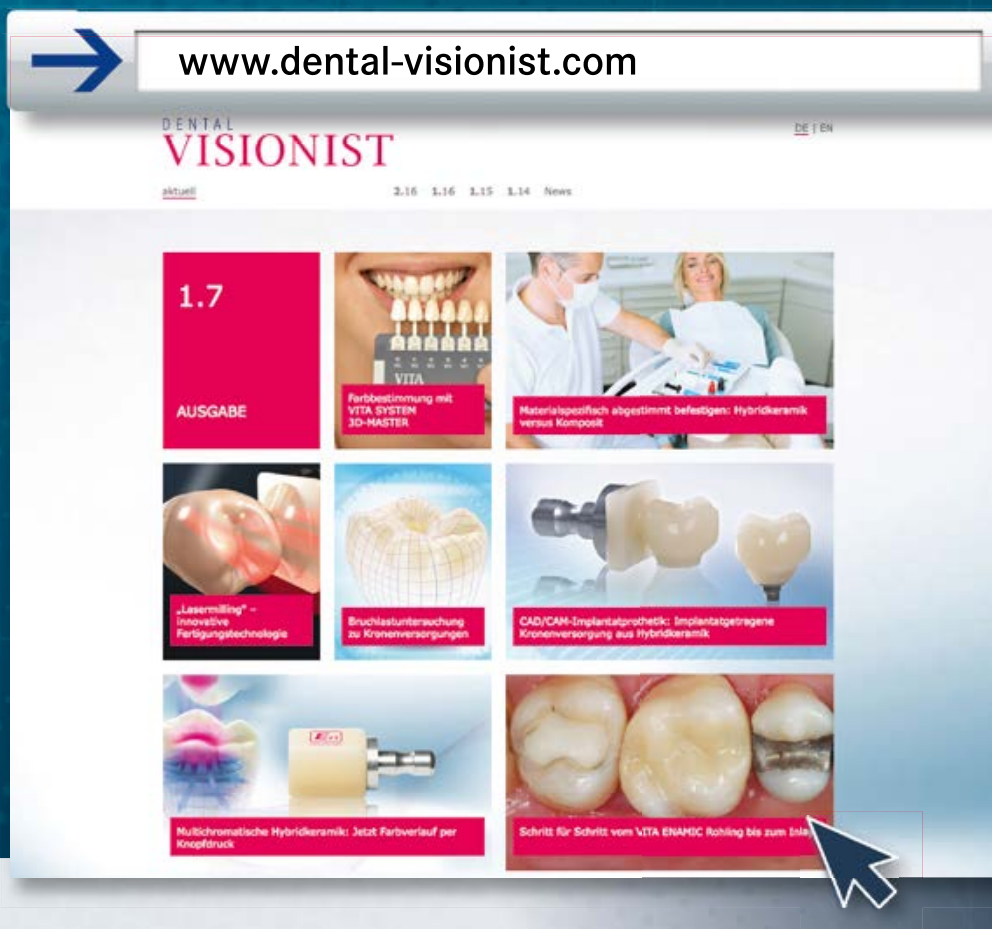alveoli. Marginal excesses were removed and polymerization was finally carried out in the pressure pot. The final, manual processing was quick and easy, thanks to precise CAM processing. The patient was highly satisfied with the natural effect of the prosthetic and the good wearing comfort of the delicately designed new restoration.

Report 07/17



RESULT: The patient was enthusiastic about the positional stability and natural effect of the VITAPAN EXCELL denture teeth.

Now available to read online!



Read all current articles as well as archived topics of DENTAL VISIONIST and find additional, exclusive online articles at www.dental-visionist.com